

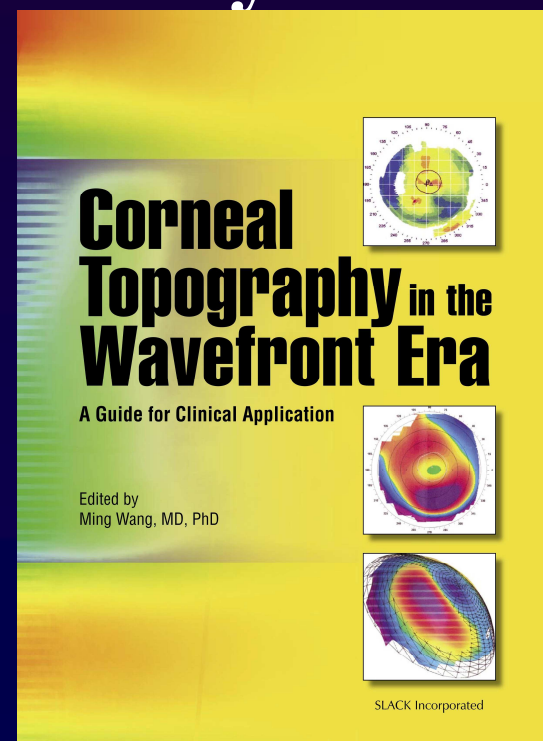
# A logical and sequential approaching to treating irregular astigmatism (caused by decentered ablation): C- CAP and CustomVue – VISX system

**Ming Wang, MD, PhD**

Clinical Associate Professor of  
Ophthalmology of University of  
Tennessee

Director, Wang Vision Institute  
Nashville, TN, USA

**New book: “Irregular astigmatism”  
(Wang eds, SLACK)**





# Collaborators

- Tracey Swartz, OD.
- Helen Boerman, O.D.
- Shawna Hill, O.D.
- Yangzi Jiang, M.D.,O.D.
- Keming Yu, M.D.,Ph.D.
- Lav Panchal, M.D.
  
- Financial interest: none.



# Irregular astigmatism caused by decentered ablation

- A decentered ablation on corneal topography;
- Increased higher order aberrations as measured using wavefront aberrometry, predominantly **coma**;
- The appearance of a **tail** on point spread functions;
- Manifest refraction with reduced best-corrected visual acuity that improves only with gas permeable lenses;
- A cylinder measurement on autorefraction and wavefront that **differs** from manifest refraction;
- A history of reduced vision immediately following surgery that fails to improve with time.

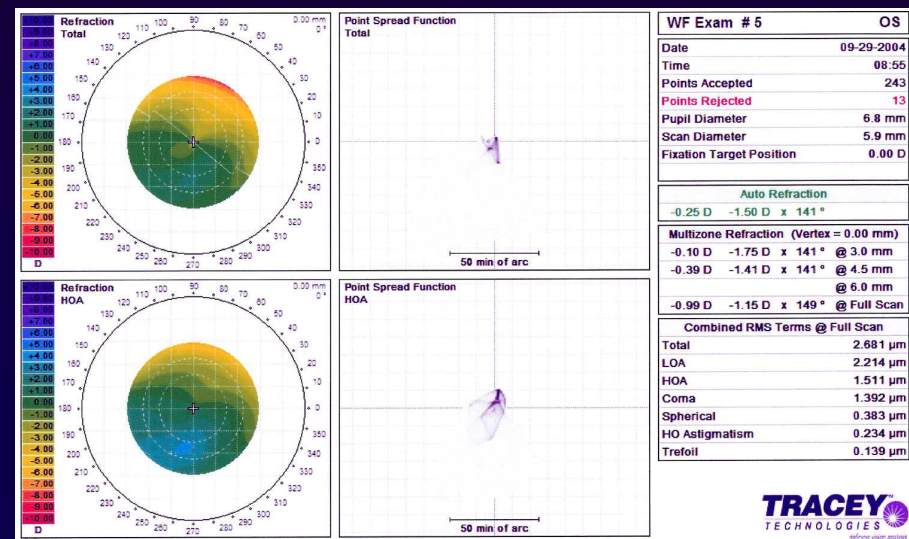
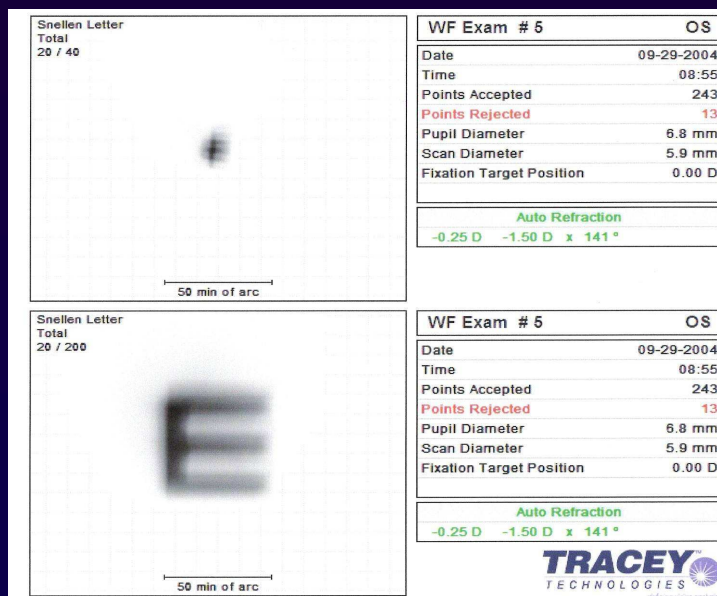


## Topo criteria for decentered ablation (height difference in elevation map)

- At least 6 microns difference on the elevation topography, from the lowest point to the highest point, over a 6.5 mm diameter or over the patient's pupil diameter as measured by the Zeiss Humphrey topographer, which ever is larger.



# Aberrometry of decentered ablation (coma)





A sequential and logical approach to treating irregular astigmatism (caused by decentered ablation) – VISX system

- Contour Cornea Ablation Pattern (C-CAP)
- CustomVue



# A step-wise general strategy for treating decentered ablation

- If cornea is mild to moderately irregular and decentration is not too severe, WaveScan **can** map it, shows **coma**, AND WS refraction is **consistent** with MR, do CustomVue custom ablation;
- If the cornea is too irregular due to large decentration and WaveScan **can not** obtain any data, do C-CAP first to *“pull the center of ablation back to the center first”*, then, do CustomVue ablation.



# FDA C-CAP indications

- Symptoms:
  - Reduced BSCVA
  - Debilitating glare
  - Monocular diplopia
  - Debilitating halos



# Clinical evaluation for C-CAP

- Required Information from primary Treatment and all enhancements:
  - BCSVA pre treatment
  - Pachymetry
  - Ablation depth
  - Flap thickness



# Clinical evaluation for C-CAP con't

- VA: UCVA, BCVA
- Refraction
  - Manifest
  - Cycloplegic
  - Stability
- Keratometry
- Pupillary Exam



# Clinical evaluation for C-CAP con't

- Evaluation of BSCVA loss
  - The etiology of the BSCVA loss or symptoms must be the result of decentered ablation
  - HCLVA: allows one to differentiate between reduced VA from irregular astigmatism vs. corneal opacification or lenticular changes



# Clinical evaluation for C-CAP con't

- Slit lamp
- Tonometry
- Dilated Fundus examination
- Pachymetry by ultrasound
- Humphrey topography



**The first step:** accurate mapping, using devices with the highest sensitivity for elevation

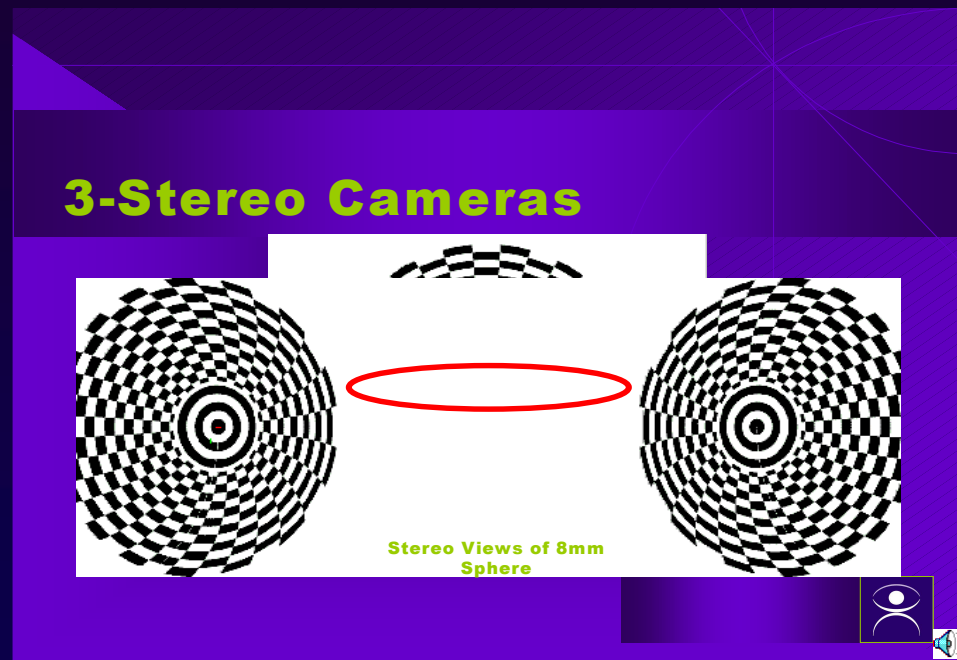## 3-D stereo corneal topographer



**astramax™**  
3 - D S T E R E O T O P O G R A P H E R



## 3-D stereo corneal topography:





# Images (3-AstraMax camera, checker board)

Exam Edit View Utilities Window Help

New Exam New Patient Find

**Patient Exam:**  
08/28/2002 11:05 - D

Exam History:  
08/28/2002 13:47 - S  
08/28/2002 11:13 - S  
08/28/2002 11:05 - D

OS OD All  
New Info Open

**Patient Information:**  
Last (\*):  
First (\*):  
Middle:  
Acct (\*): 01371  
Birth (\*): 05/11/1947  
Sex (\*): Female  
Phys: Ming Wang  
Ref Phys:  
Ref Group:  
Diagnosis:  
Notes:

**Raw Eye Images** Wang Vision Institute

08/28/2002 11:05: OD

**Placido Images**

**Scotopic Pupil Images, Size: 5.454 mm**

**Photopic Pupil Images, Size: 3.968 mm**

**Cross/Pachymetry Images**

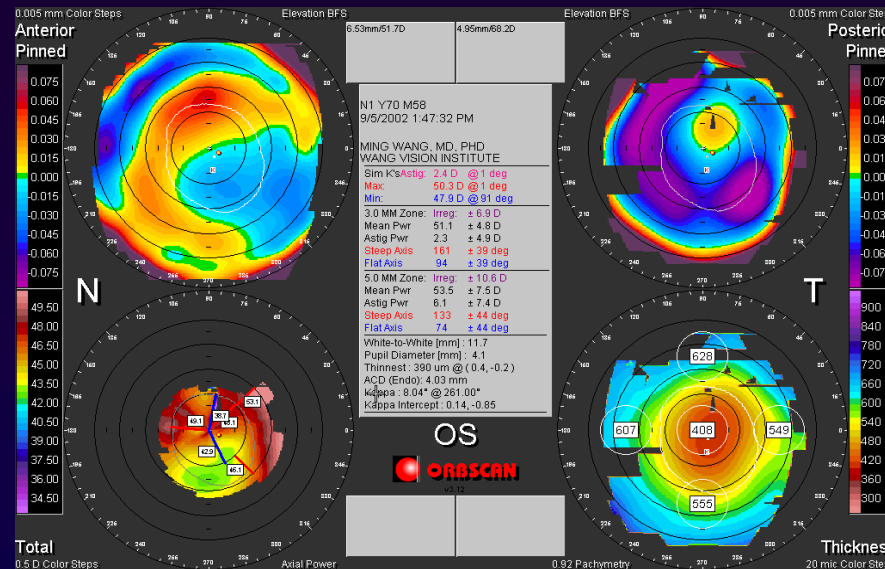
**LASERSIGHT**

Copyright © 2002 LaserSight Technologies, Inc.

Save Process Print Help



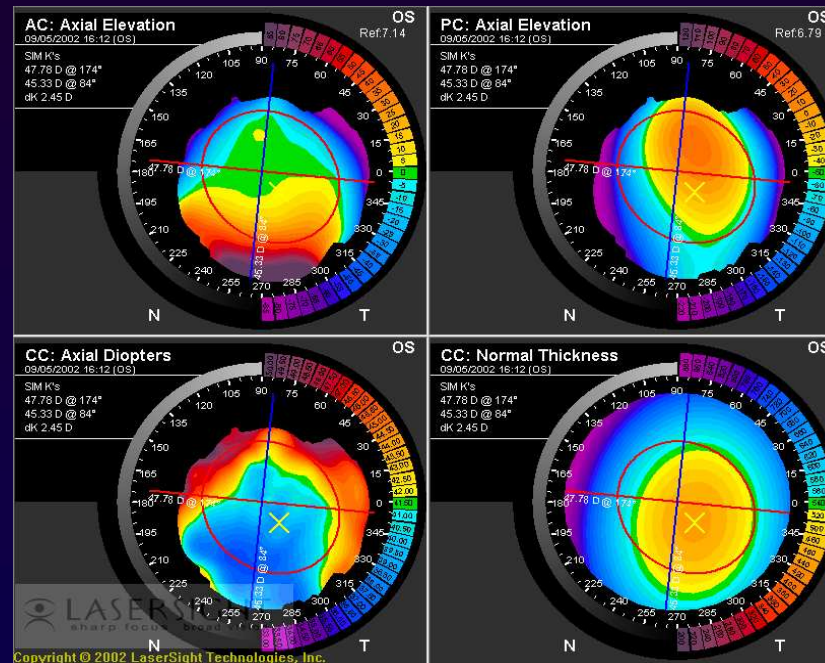
**Case 1: Improved sensitivity using 3-D topo:  
Diplopia after LASIK, causes unclear, but topo measurement  
inconsistent and variable due to dry eyes.**



**Repeated scans were highly variable and showed  
artifactual “steepening”, due to dry eyes.  
Topographic systems that require long eye  
exposure time are more prone to aberrant optical  
artifact arising from dry corneal surface.**



## Case 1 con't: AstraMax's 3-D successfully showed positive finding (of **decentered treatment**).



**AstraMax, with its short eye exposure time (0.2 sec), and multi-camera incoming shots, is less likely to be affected by optical artifact due to dry corneal surface.**



# Step-wise approach to C-CAP to treat decentered treatment

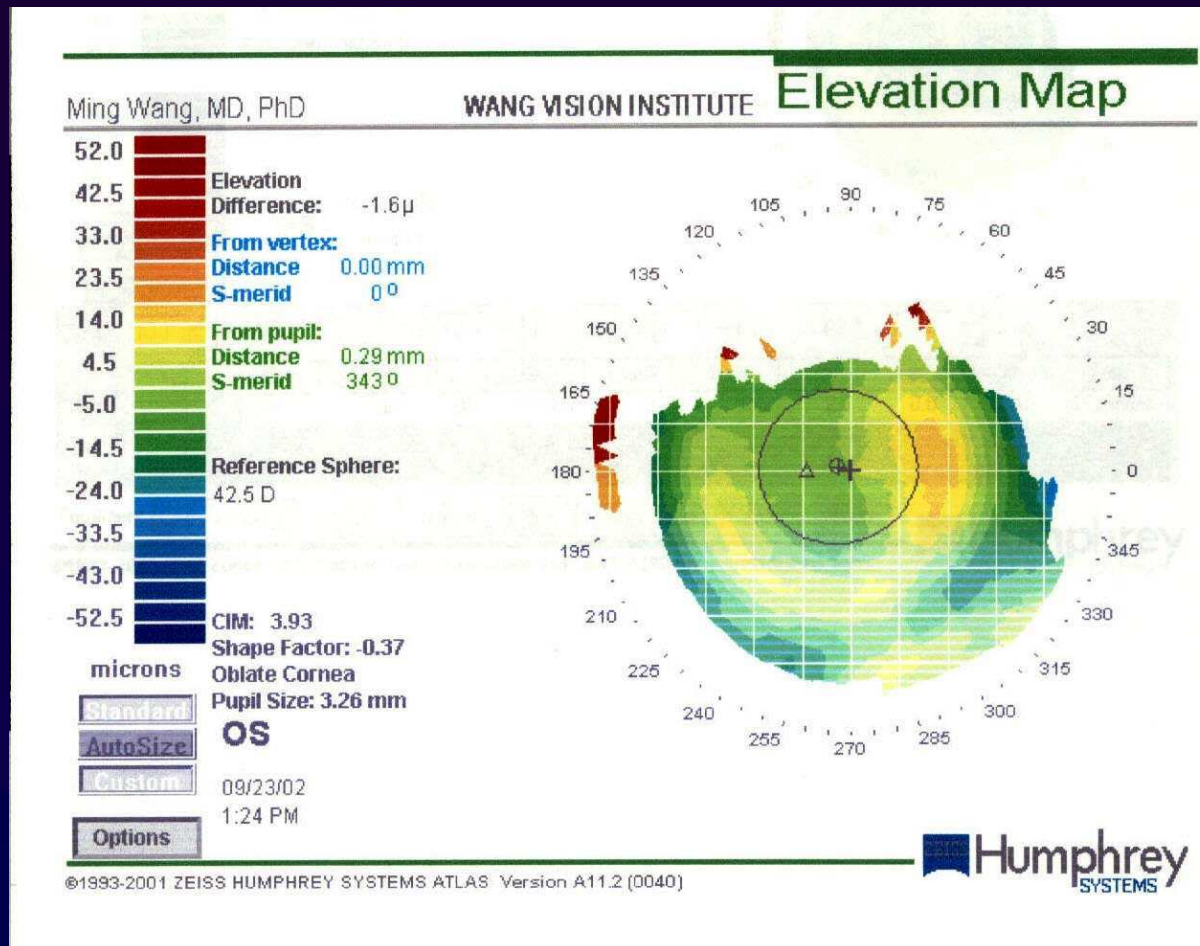
- ❖ Humphrey Atlas topographer

- ❖ Vision Pro software

- Customized ablation program
- Demonstrate the ablations effect on topography

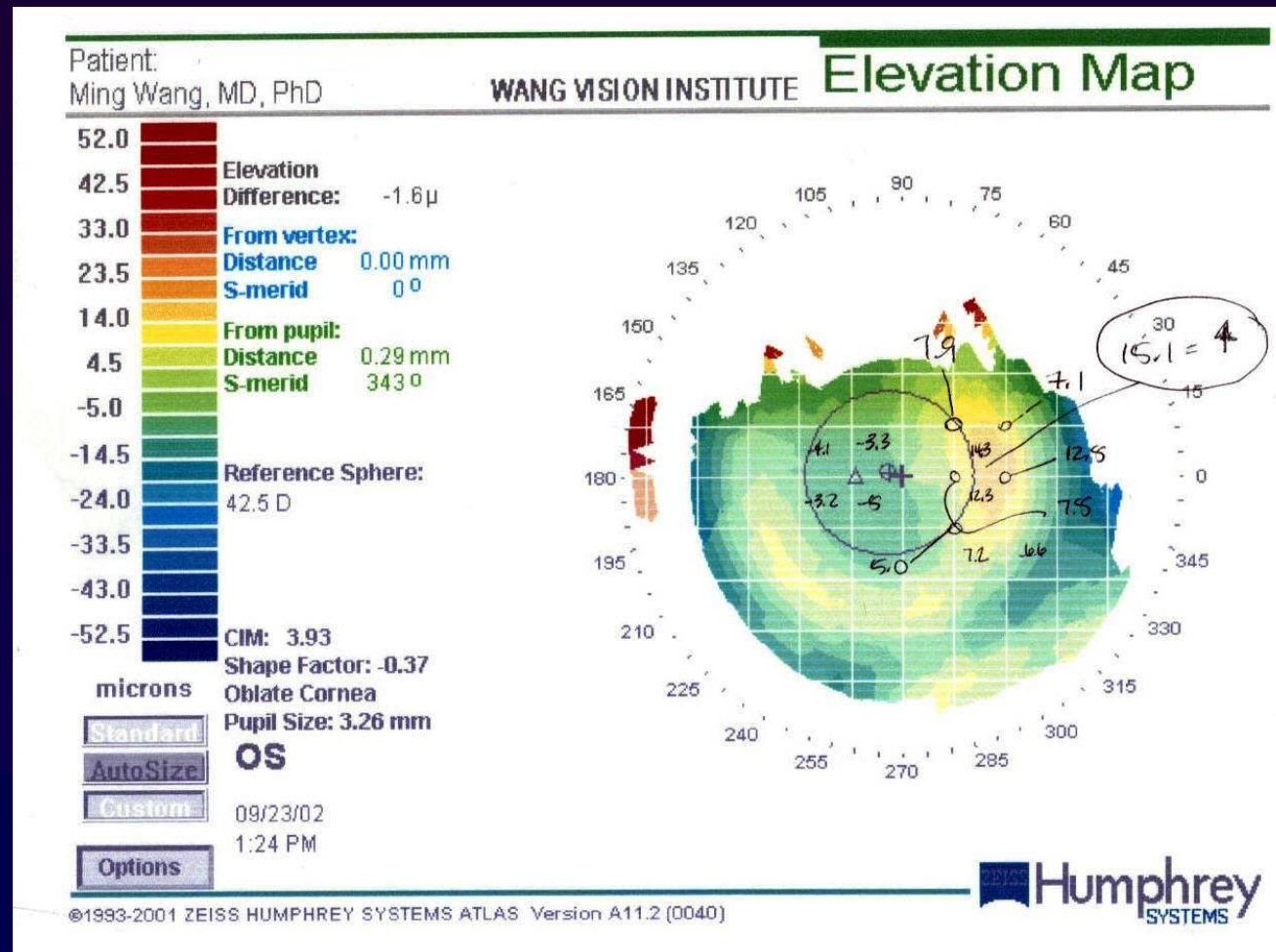


# Step 1: Elevation Map





# Step 2: Locate highest point



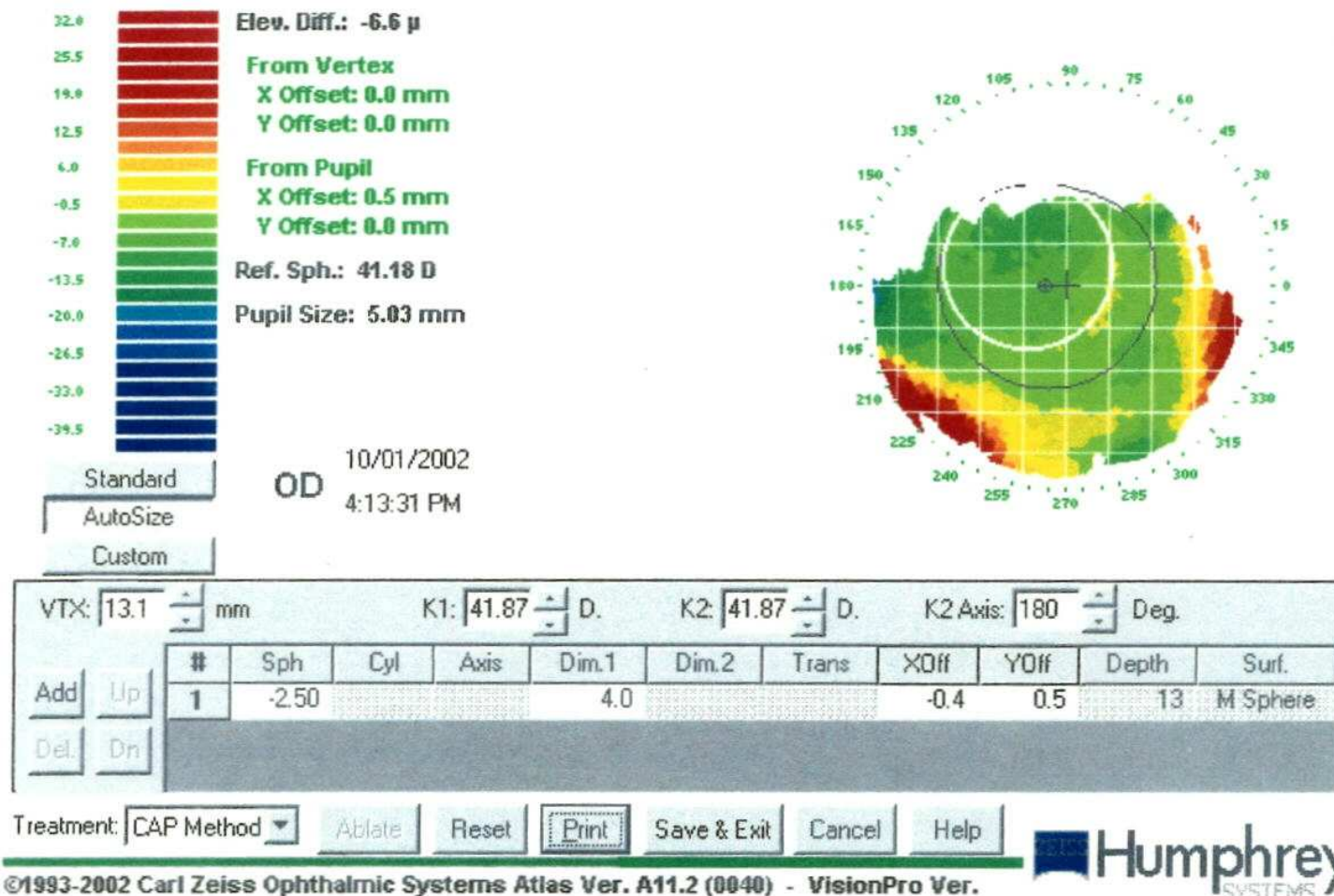


## Step 3: C-CAP ablation patterns

- Myopic Sphere
- Myopic Astigmatism
- Myopic Ellipse

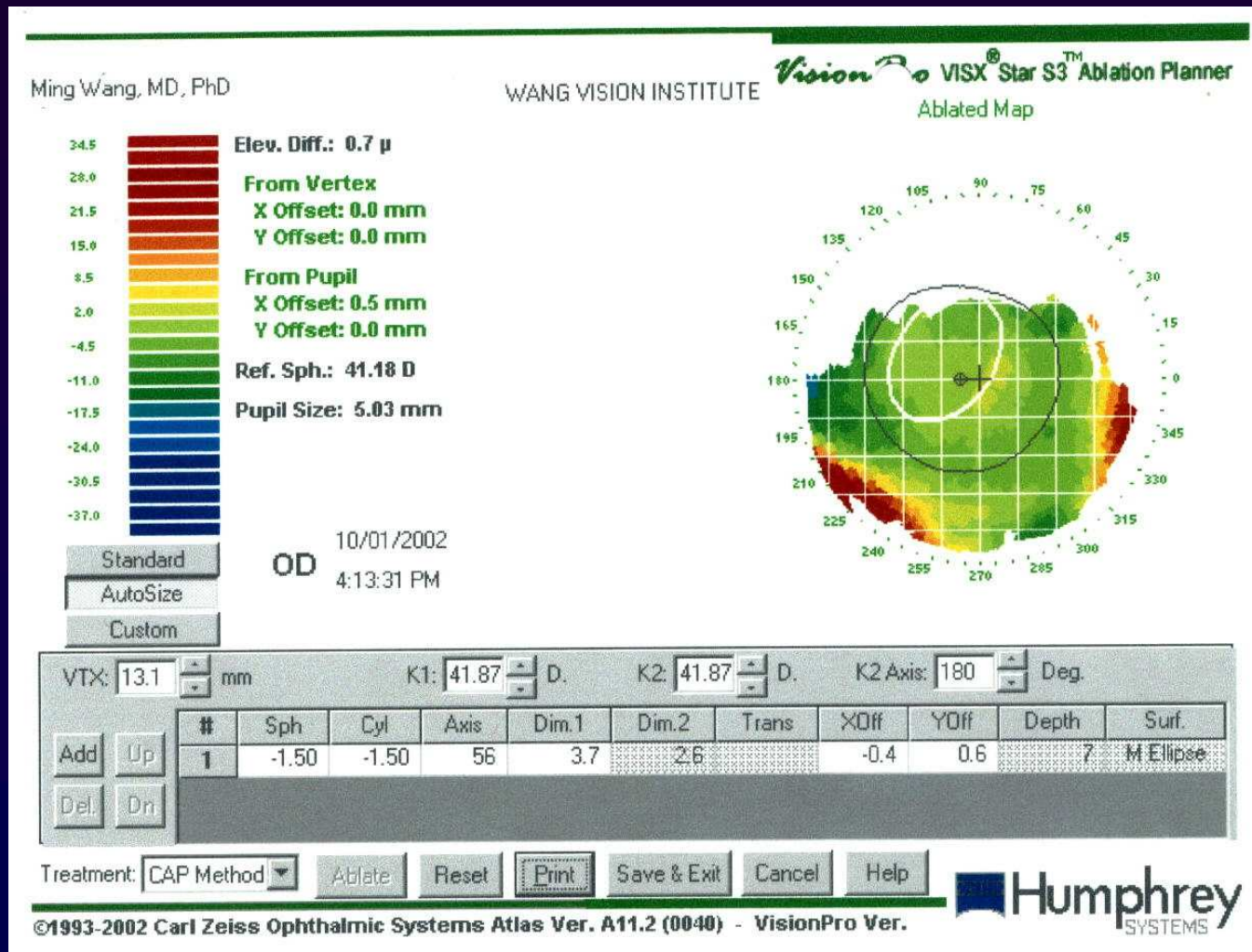


# Spherical Treatment



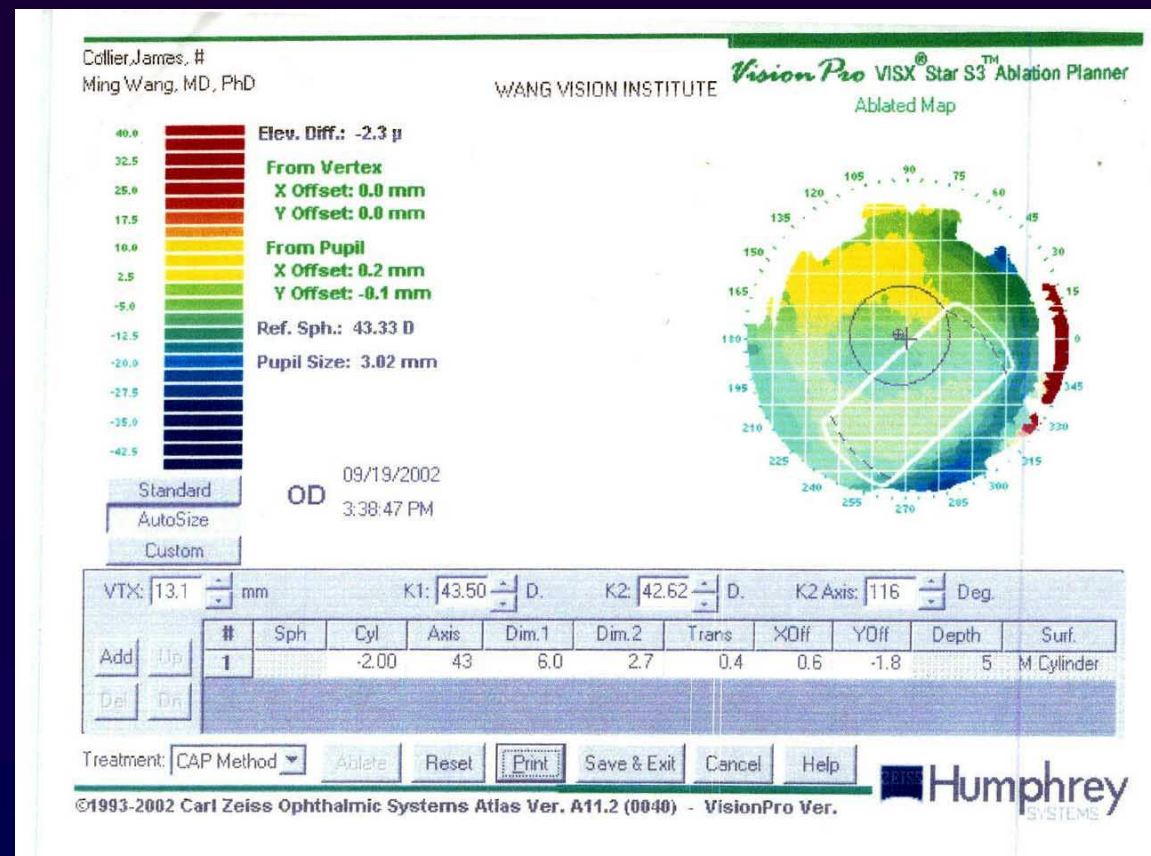


# Myopic Elipse Treatment





# Myopic Astigmatism Treatment





# Combination Treatments

Ming Wang, MD, PhD

WANG VISION INSTITUTE

Vision Pro VISX Star S3 Ablation Planner

Ablated Map

Elev. Diff.: -2.3  $\mu$

From Vertex  
X Offset: 0.0 mm  
Y Offset: 0.0 mm

From Pupil  
X Offset: 0.2 mm  
Y Offset: -0.1 mm

Ref. Sph.: 43.33 D

Pupil Size: 3.02 mm

Standard  
AutoSize  
Custom

OD 09/19/2002 3:38:47 PM

VTX: 13.1 mm K1: 43.50 D. K2: 42.62 D. K2 Axis: 116 Deg.

| # | Sph | Cyl   | Axis | Dim.1 | Dim.2 | Trans | XOff | YOff | Depth | Surf.      |
|---|-----|-------|------|-------|-------|-------|------|------|-------|------------|
| 1 |     | -2.50 | 147  | 4.0   | 1.8   | 0.5   | 0.9  | 1.0  | 3     | M Cylinder |
| 2 |     | -2.00 | 43   | 6.0   | 2.7   | 0.4   | 0.6  | -1.8 | 5     | M Cylinder |

Treatment: CAP Method

Ablate Reset Print Save & Exit Cancel Help

©1993-2002 Carl Zeiss Ophthalmic Systems Atlas Ver. A11.2 (0040) - VisionPro Ver.

Humphrey SYSTEMS



## Step 4: Print final pattern

- Documentation for Chart:
  - Includes all parameters necessary to complete treatment
  - Use this data to program the laser



## Step 5: Input patterns into laser

- CAP card required
- Software update is required



## Step 6: Perform treatment

- Technique identical to performing typical enhancement
- Short treatment times



# C-CAP Case JC

- 47 yo Male
- S/P LASIK OU January 2001 by area surgeon with grade 4 DLK requiring flap lift OU at one week
- CC: “Visual distortion with glasses. RGP’s required for comfortable vision, but CL’s are making my eyes dry”

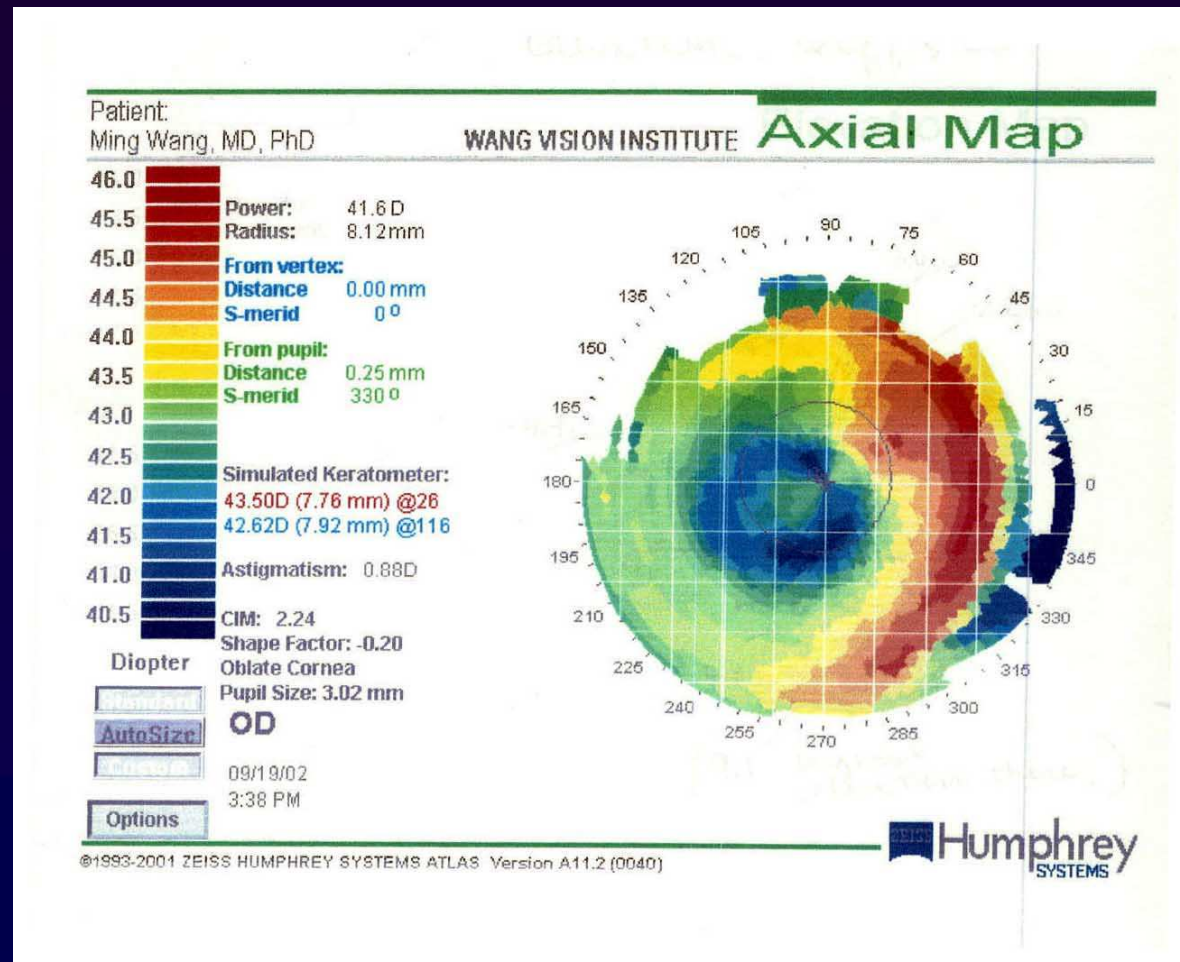


## C-CAP Case JC

- Unaided VA: 20/80
- MR -1.25+1.75 x 45, 20/30
- Cyclo -1.00+1.75 x 45
- RGP VA 20/20
- Ultrasound Pach 578/588/574 microns
- IOP, anterior and posterior segment healthy

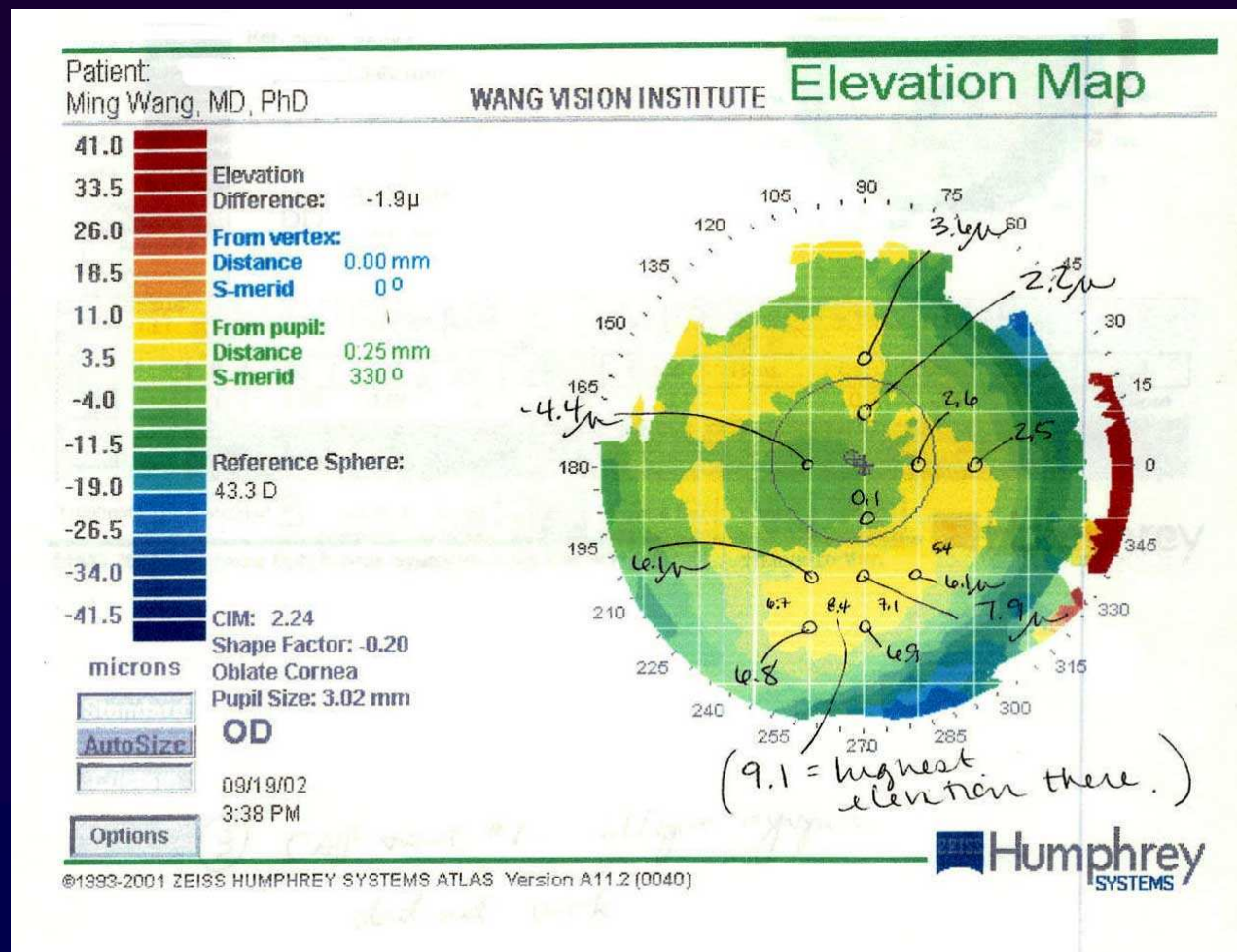


# Case JC “Decentration not due to primary laser treatment, but due to **secondary tissue digestion** (DLK)”



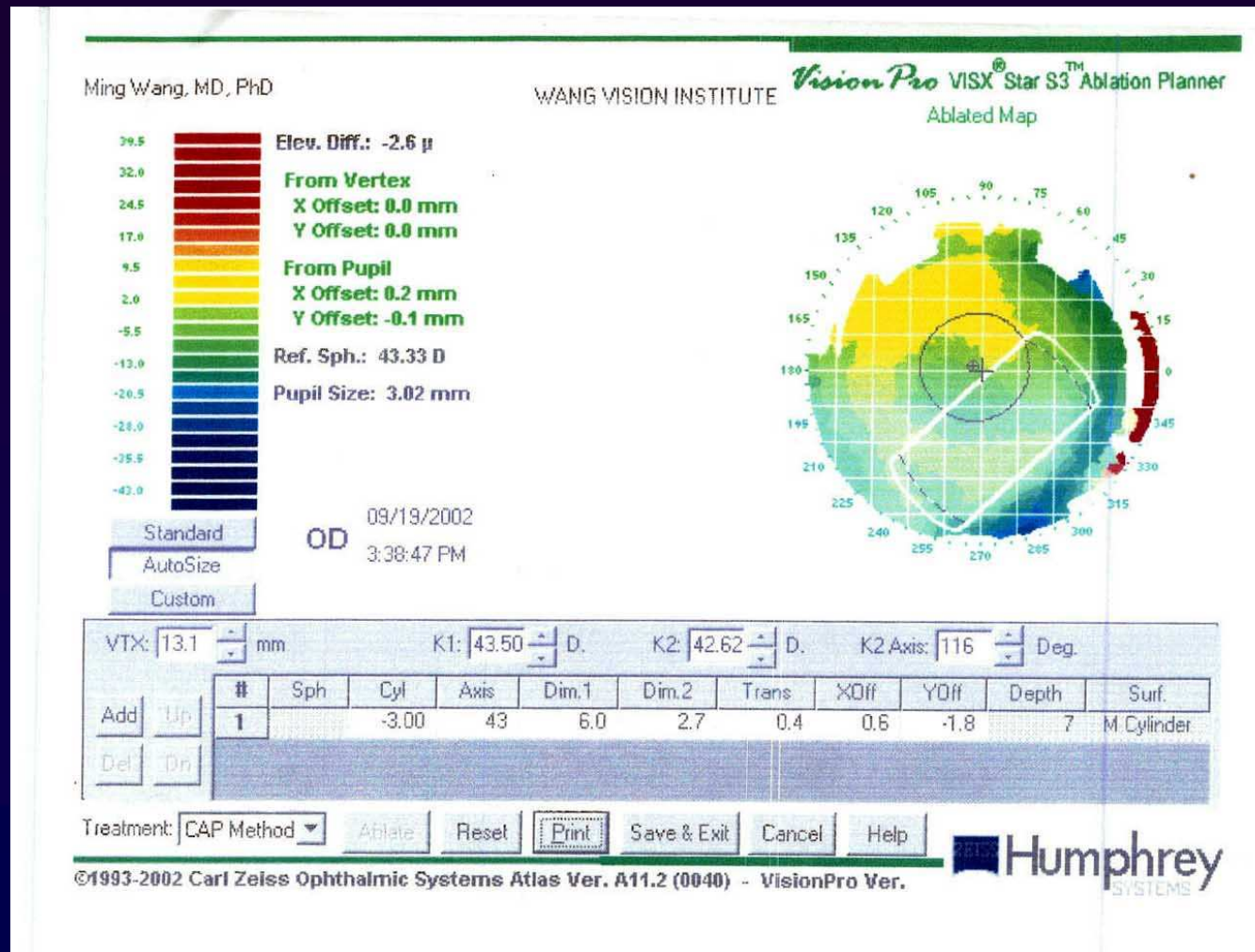


# C-CAP Case JC



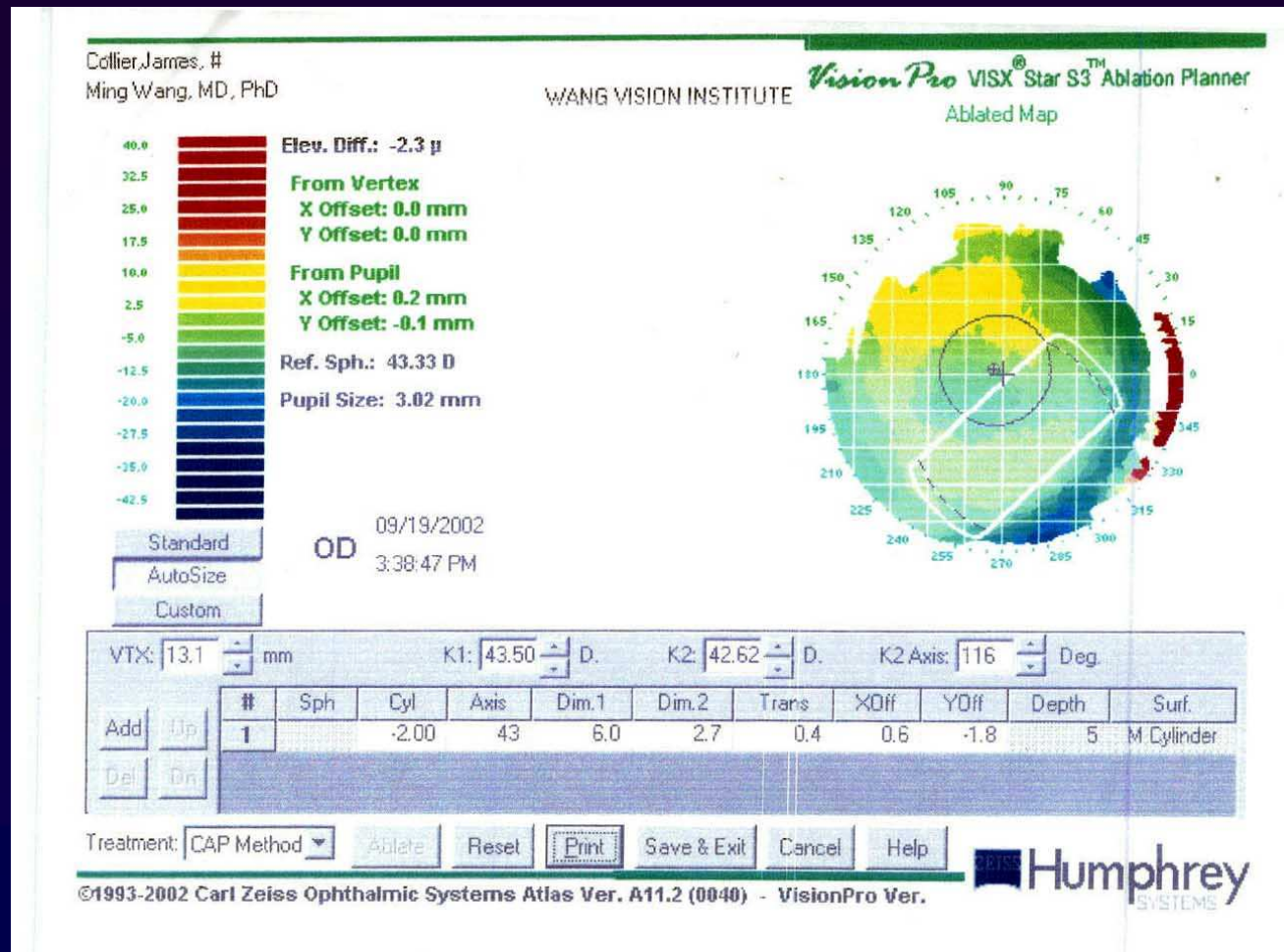


# C-CAP Case JC



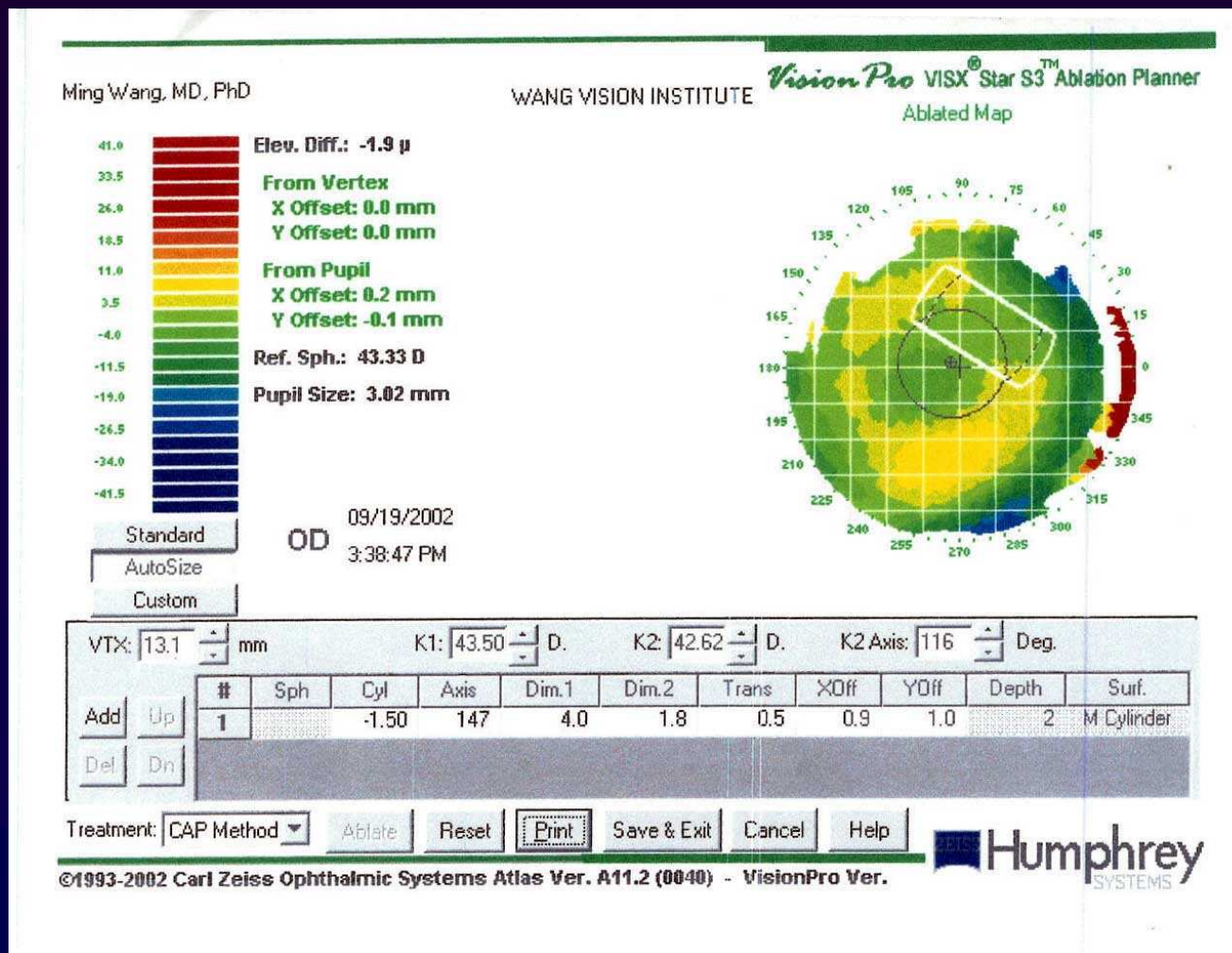


# C-CAP Case JC



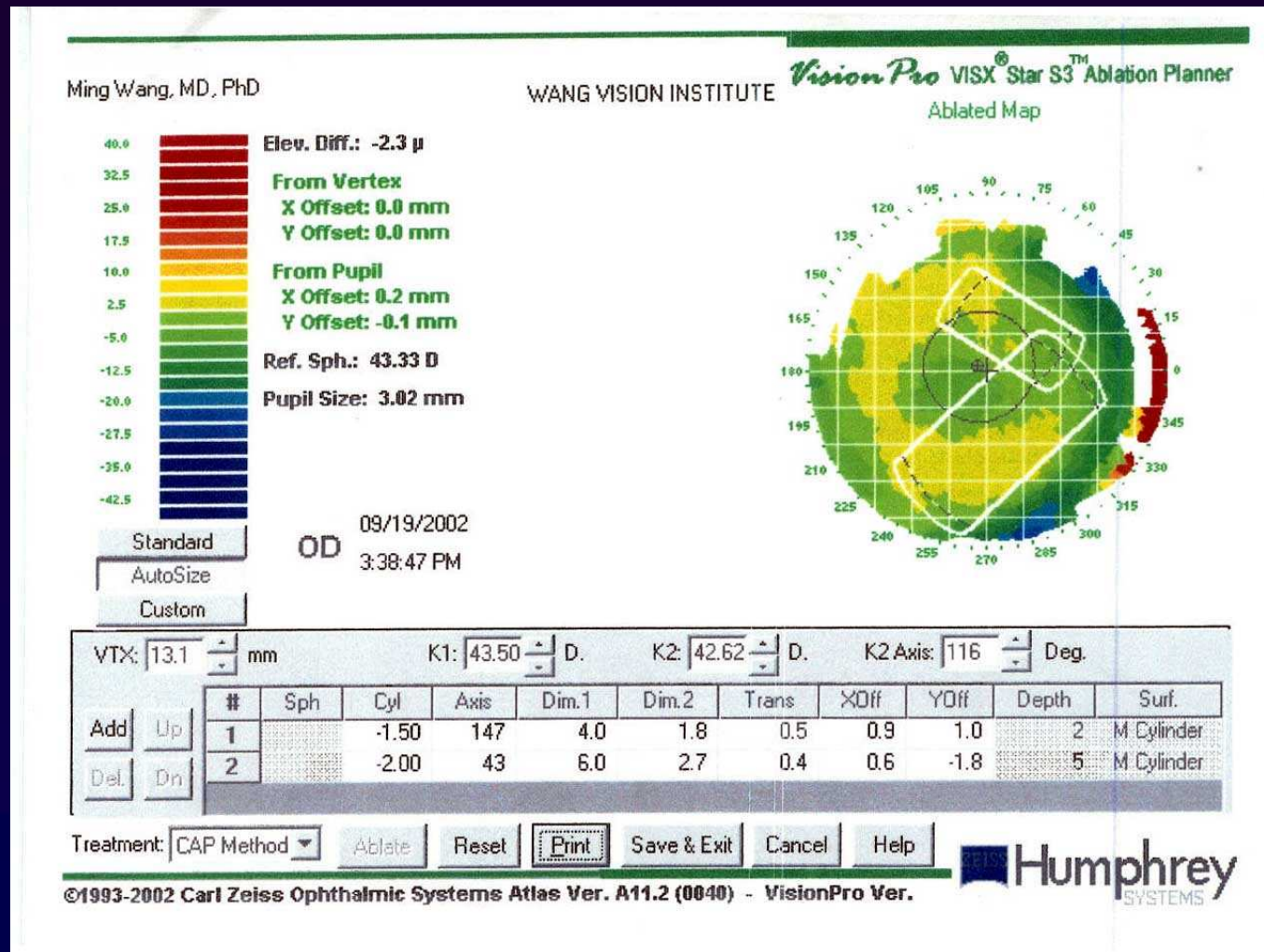


# C-CAP Case JC



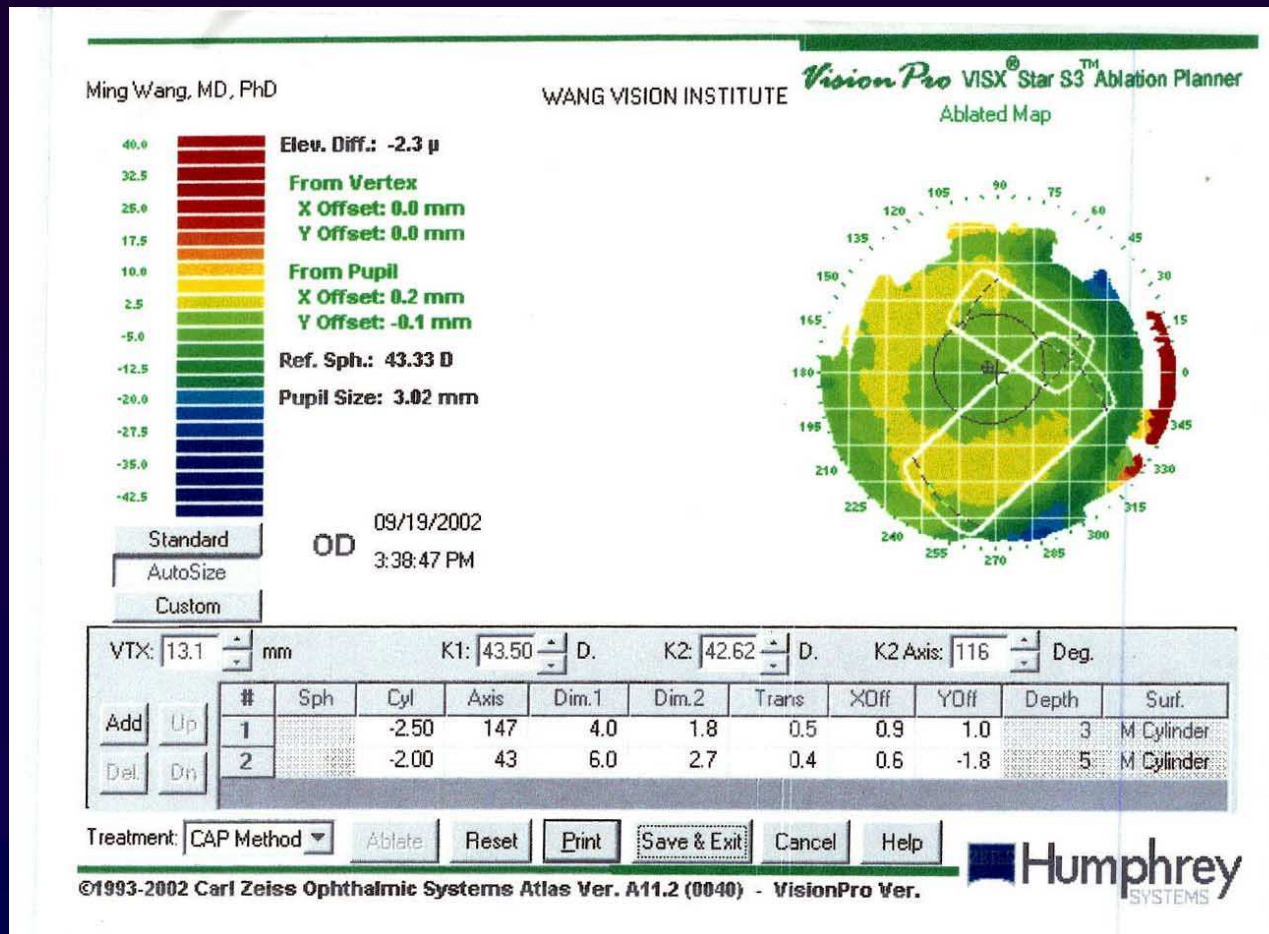


# C-CAP Case JC



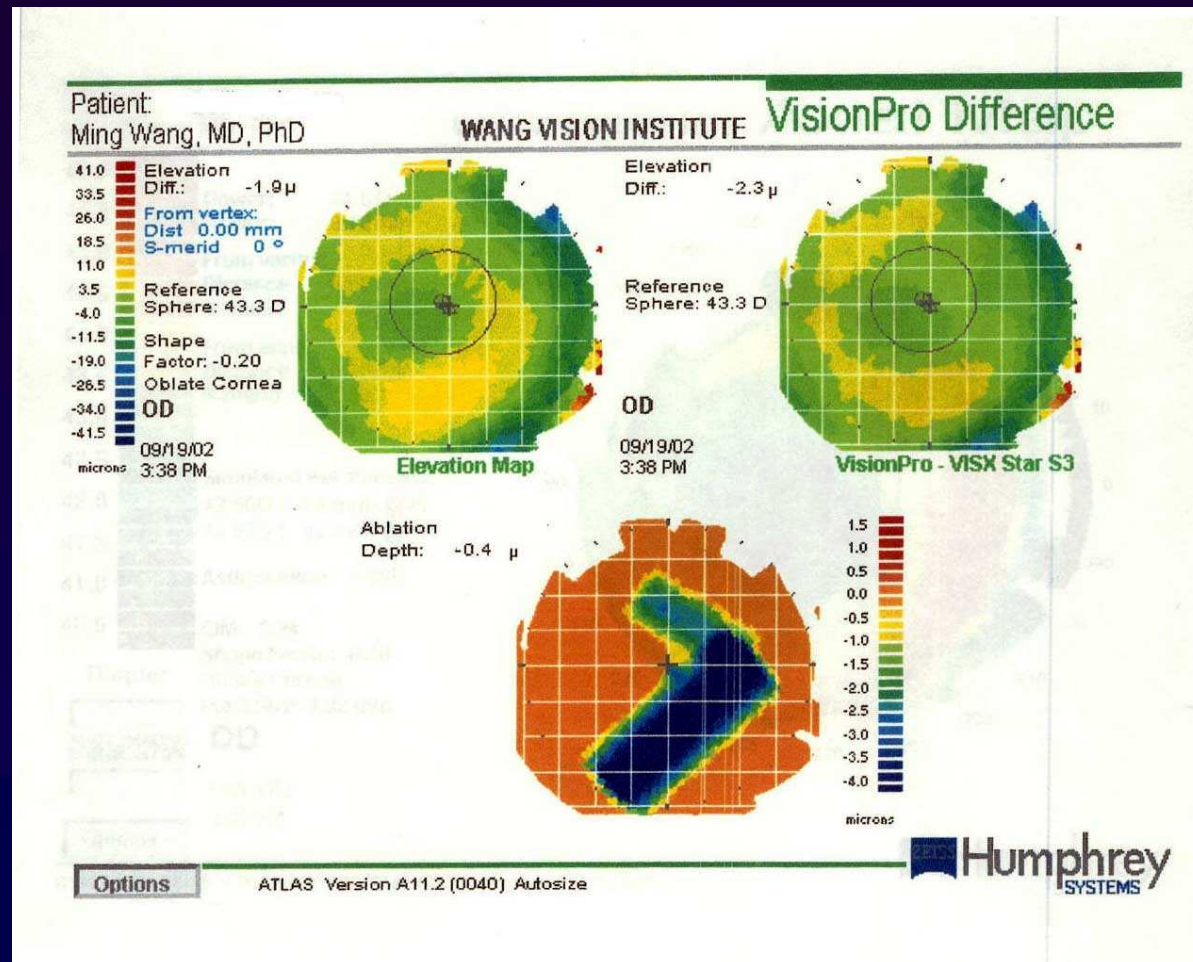


# C-CAP Case JC





# C-CAP pre, post and difference elevation map (Case JC)





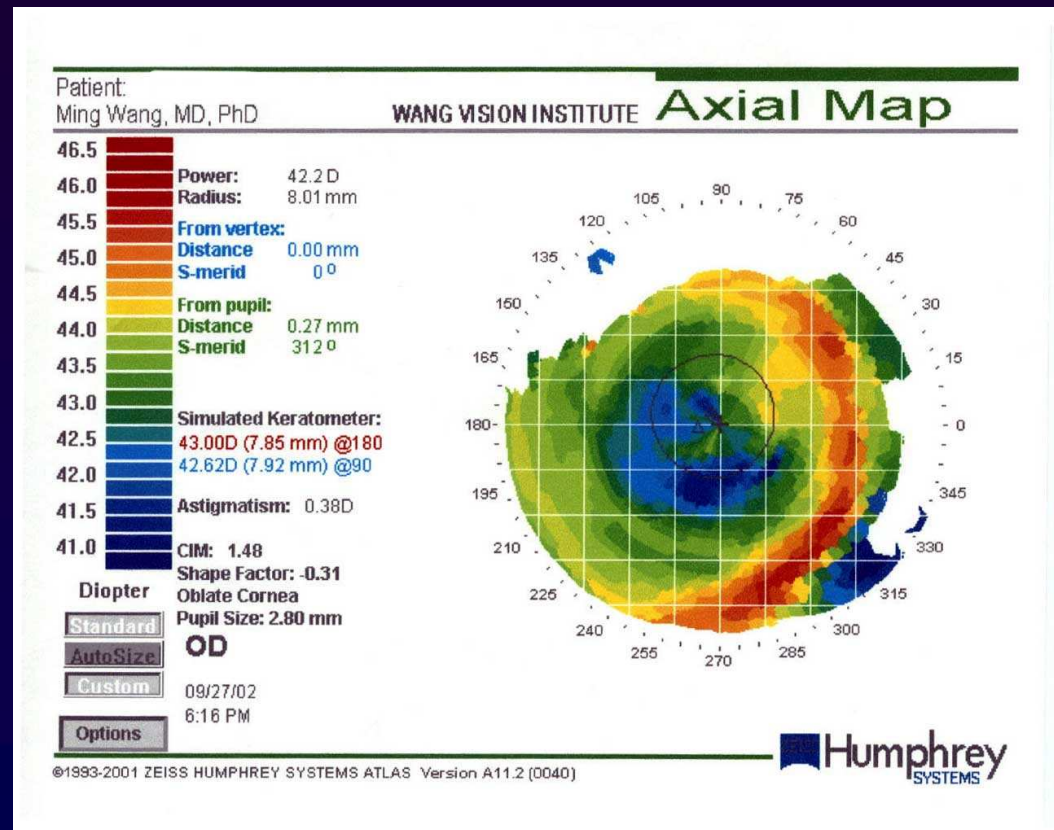
# C-CAP Case JC

- Final treatment plan:
  - M Cylinder I: 3 microns x 147 (4.0x1.8 mm);  
Offsets: X +0.9 mm, Y +1.00
  - M Cylinder II: 5 microns x 043 (6.0x2.7 mm);  
Offsets: X +0.6 mm, Y -1.8mm



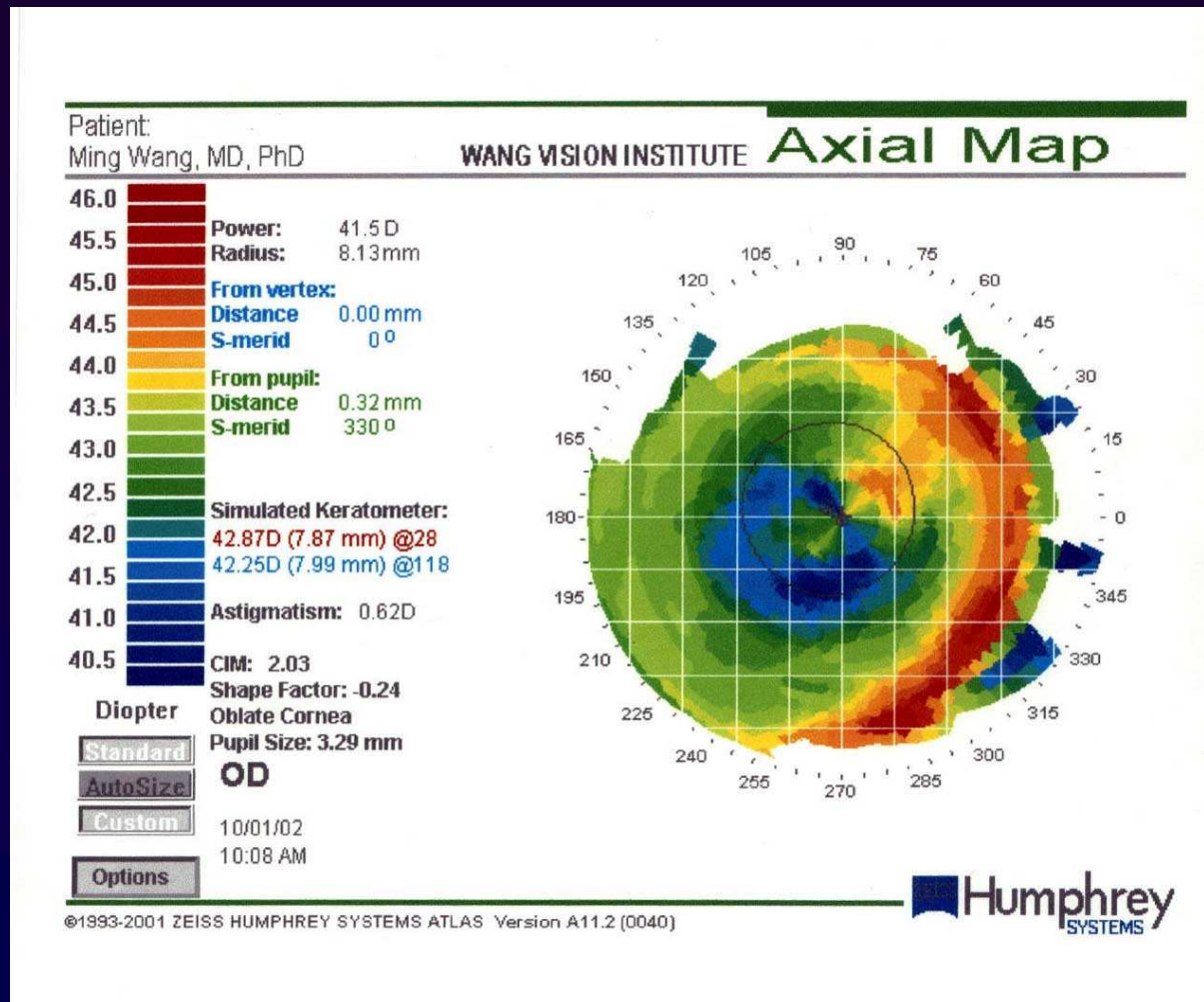
# Case JC: 1 day s/p C-CAP

- POD #1 CC: smear is much better, equal to the other eye
- VA sc 20/60



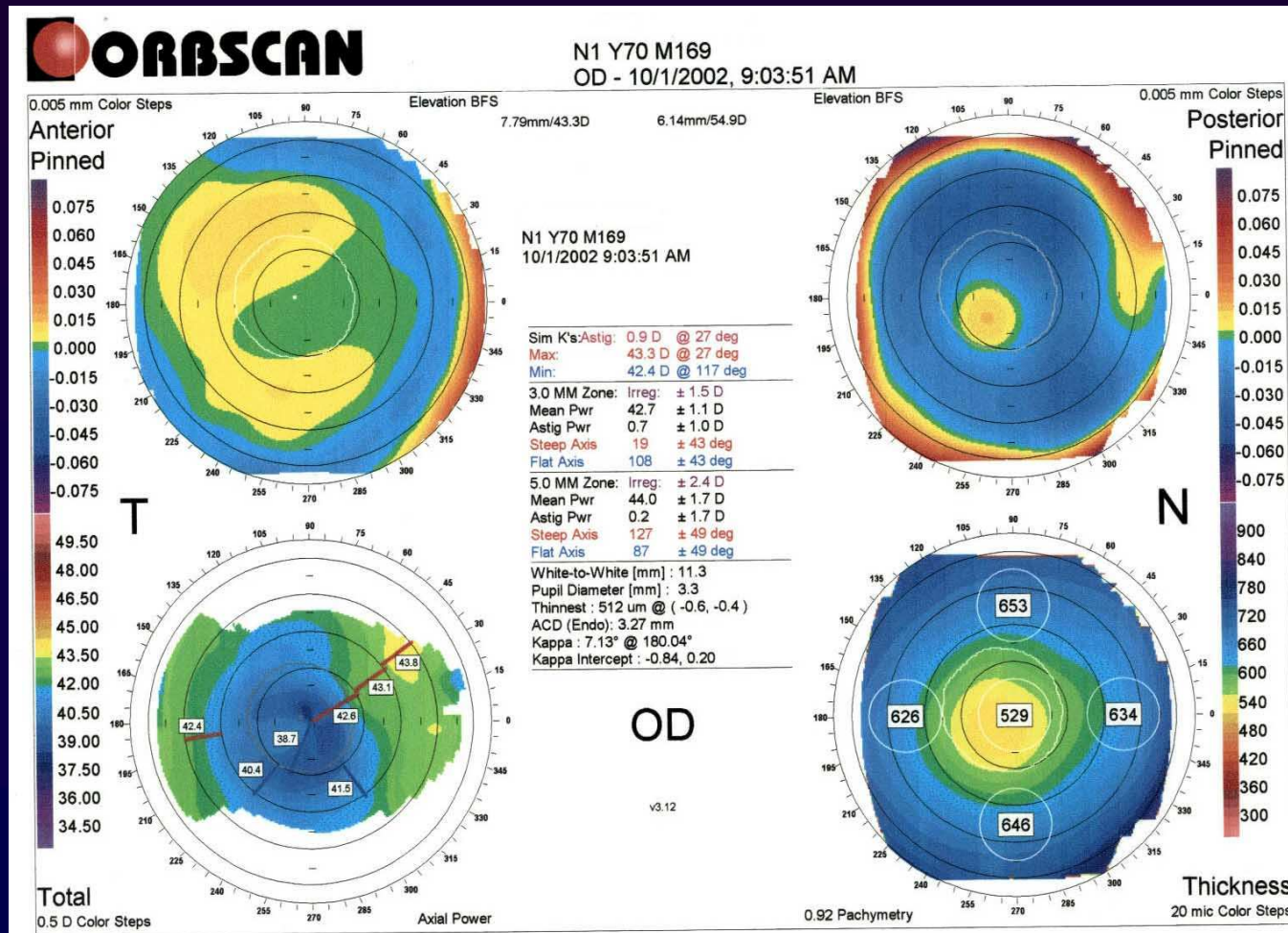


# Case JC: 1 week s/p C-CAP





# Case JC: 1 week s/p C-CAP





# Case JC: 1 month s/p C-CAP

Pre-Op:

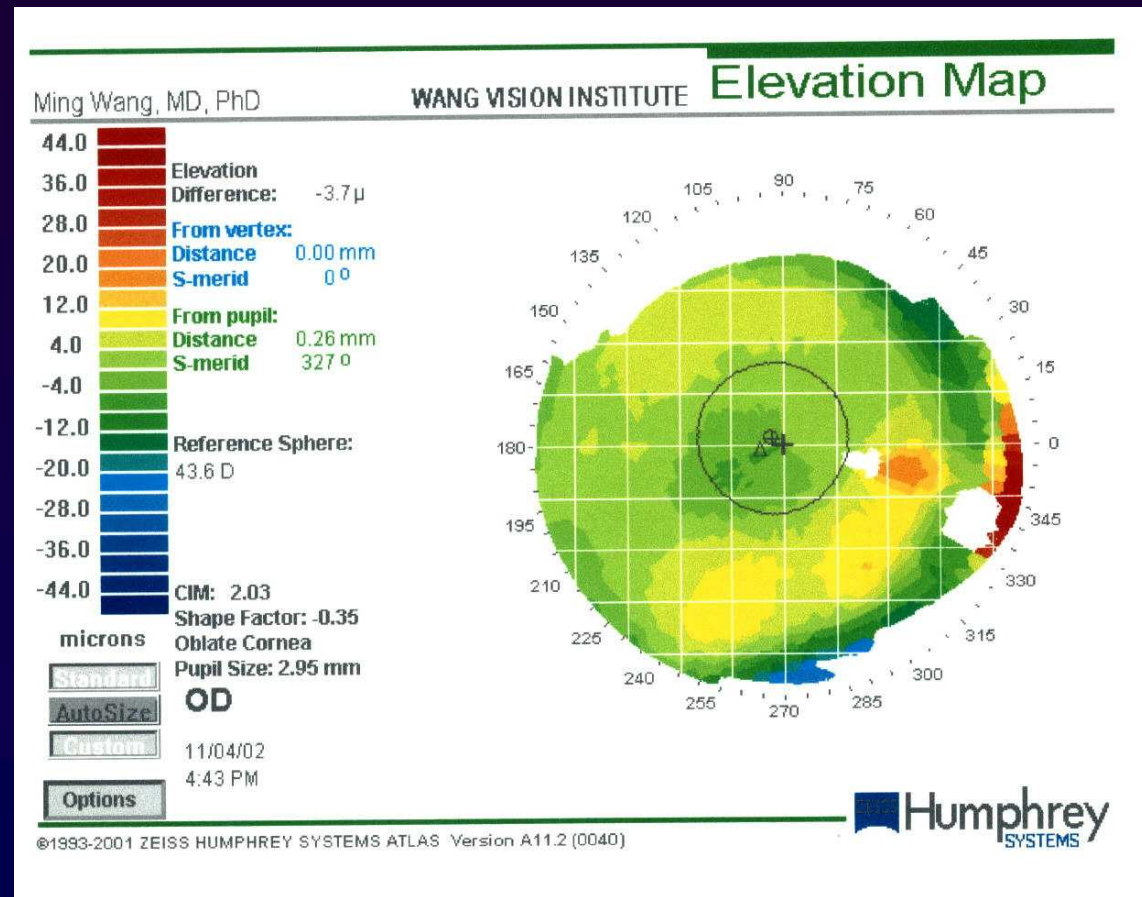
Unaided VA: 20/80

MR  $-1.25+1.75 \times 45$   
20/30

1 Mo PO:

Unaided VA: 20/70

MR  $-0.75+1.00 \times 31$   
20/20





# Case JC: 3 months s/p C-CAP

- JC returned wearing **soft** toric CI for refractive correction, reporting nearly 100% resolution of the visual distortion
- VA sc 20/30, with BCVA of 20/20
- Requested refractive enhancement, which was successfully performed at 4 months



## Second C-CAP Case: PG

- 49 yo Male
- S/P LASIK OU 1997 with enhancements OU 1998 by area surgeon
- CC: “Double Vision”

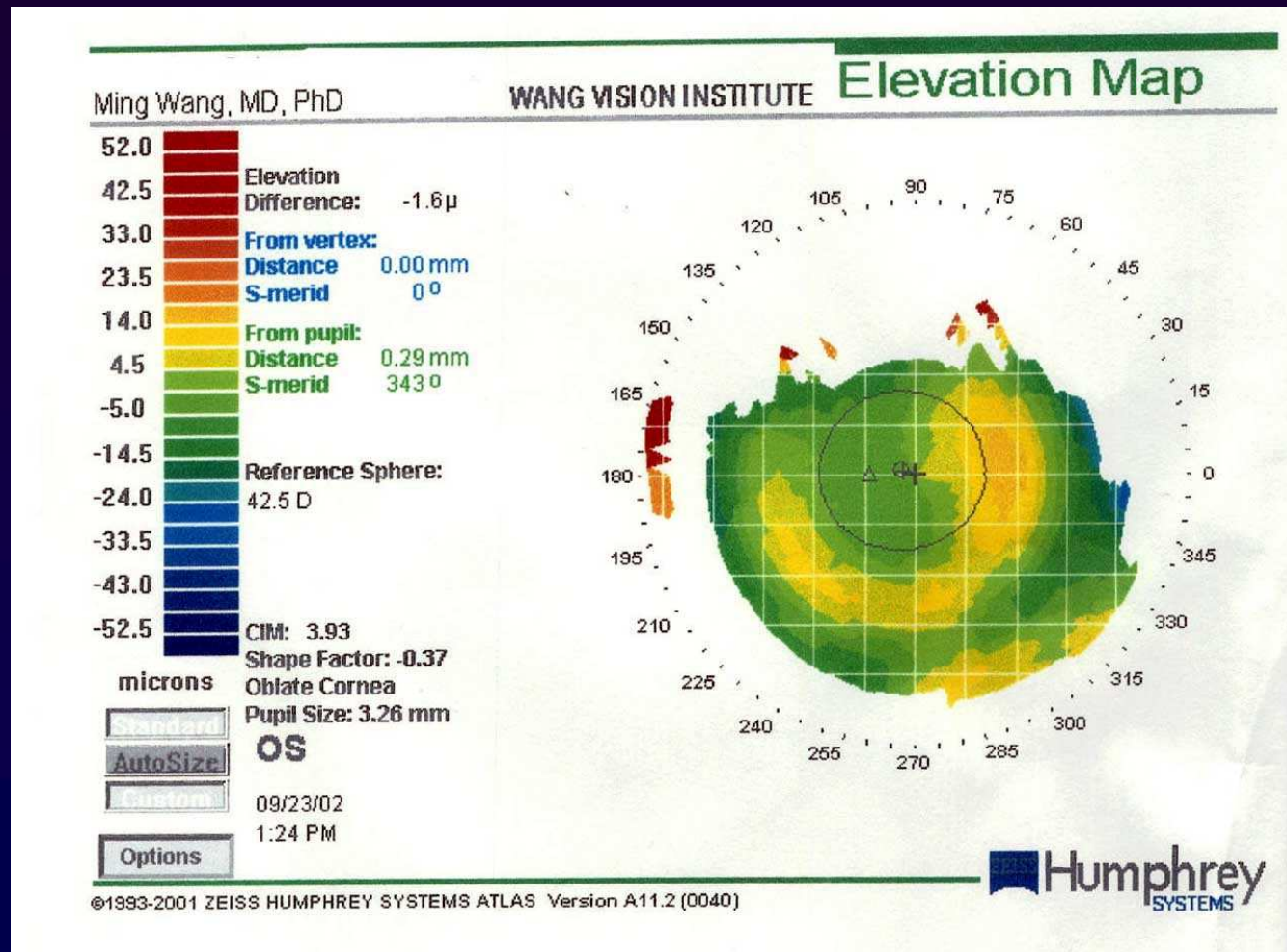


# C-CAP Case PG

- Unaided VA: 20/60
- MR -2.75+1.75 x 135, 20/30
- Cyclo -2.75+1.00 x 135
- RGP VA 20/40 (poor fit) but subjective improvement in VA with CL noted
- Ultrasound Pach 475/480/477 microns
- IOP, anterior and posterior segment healthy

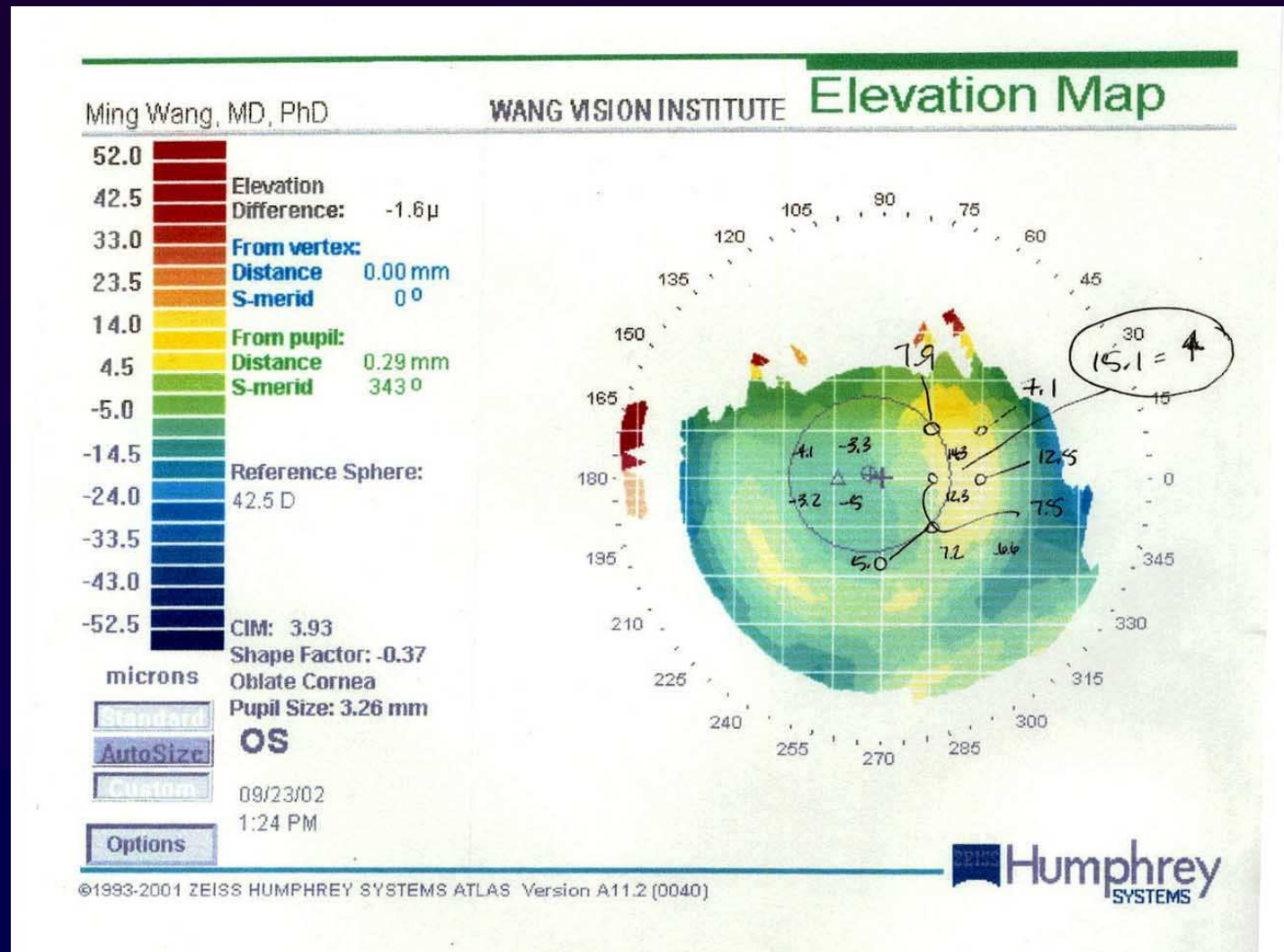


# Elevation map (C-CAP Case PG)



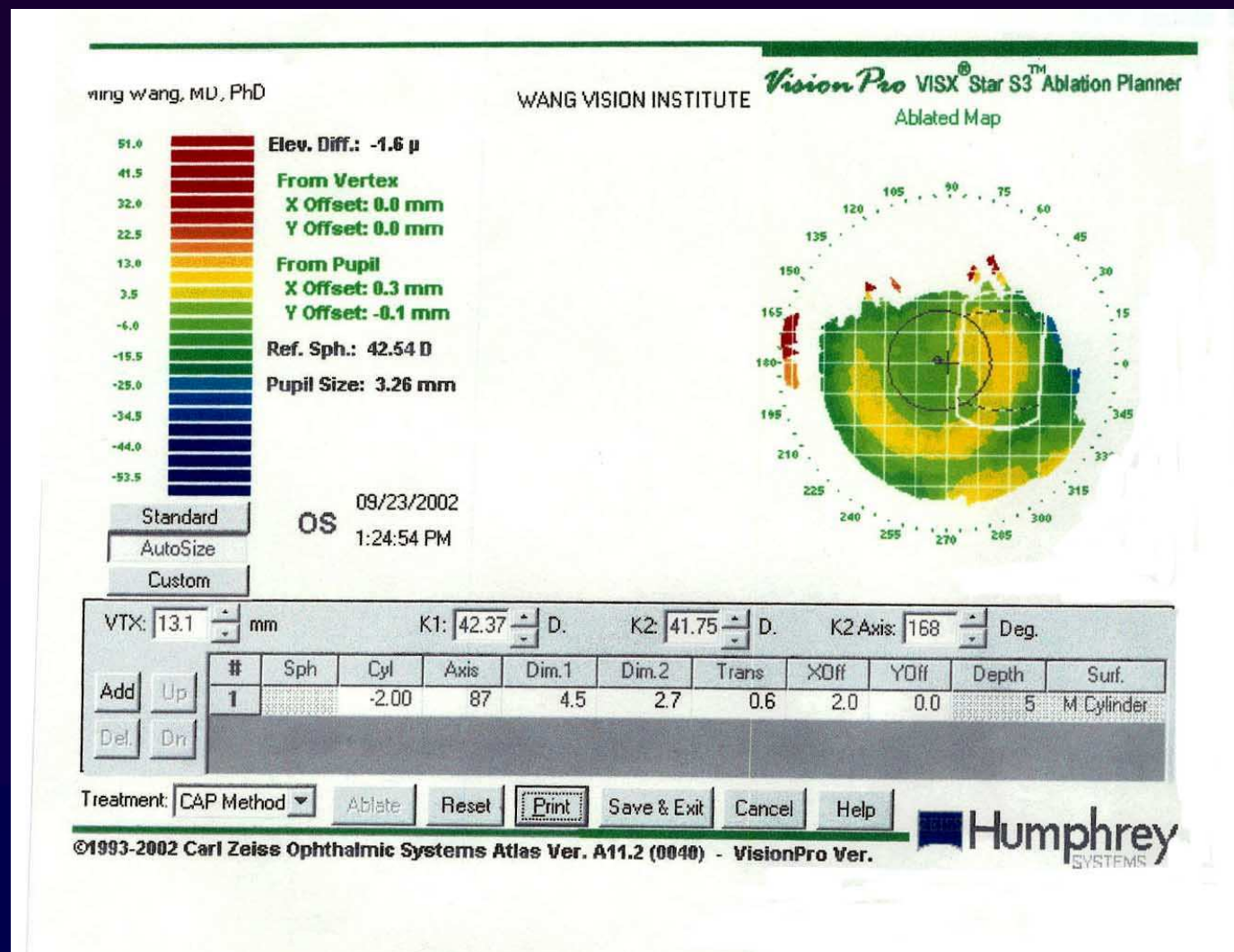


# Elevation map with height values (PG)



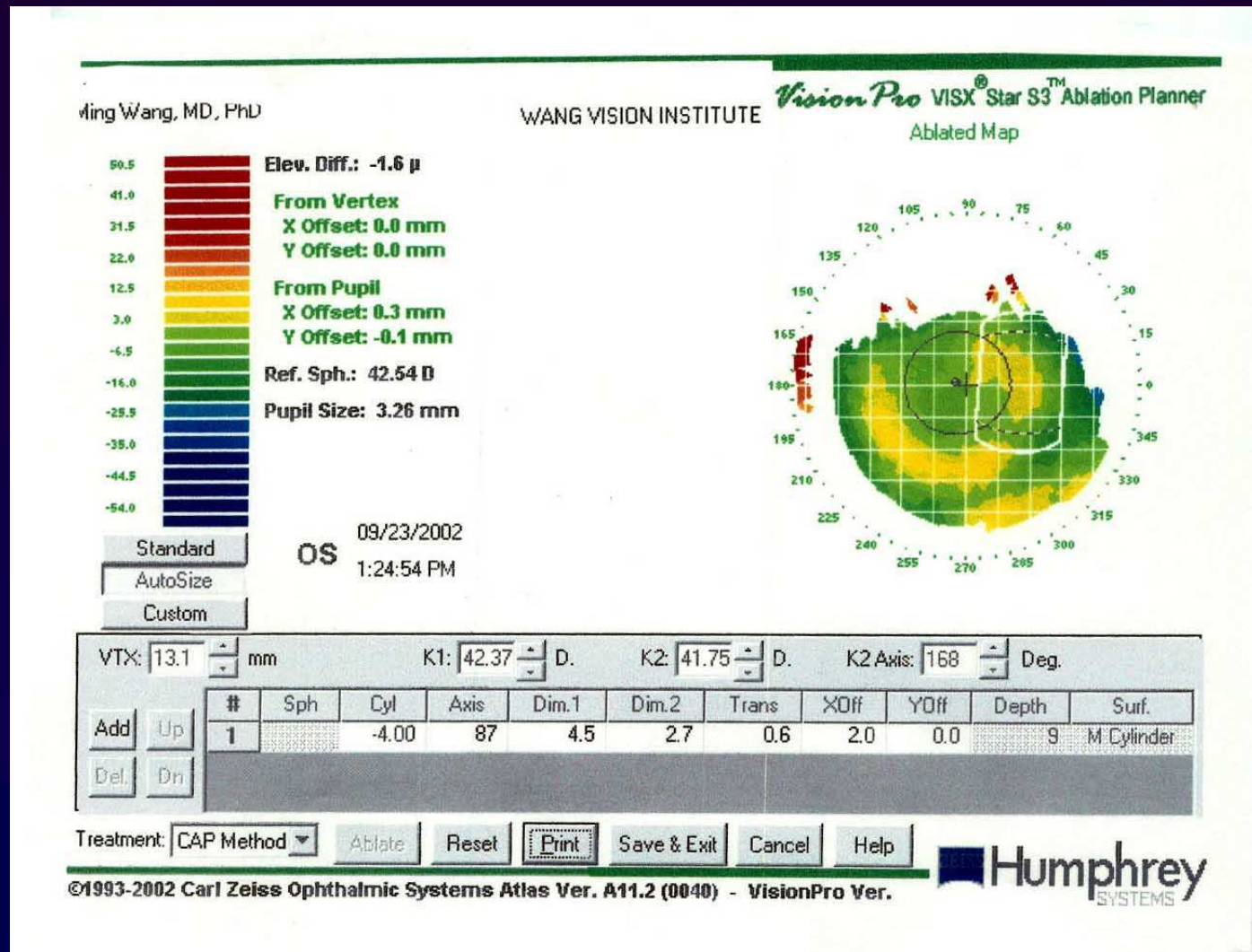


# Treatment plan (C-CAP PG)



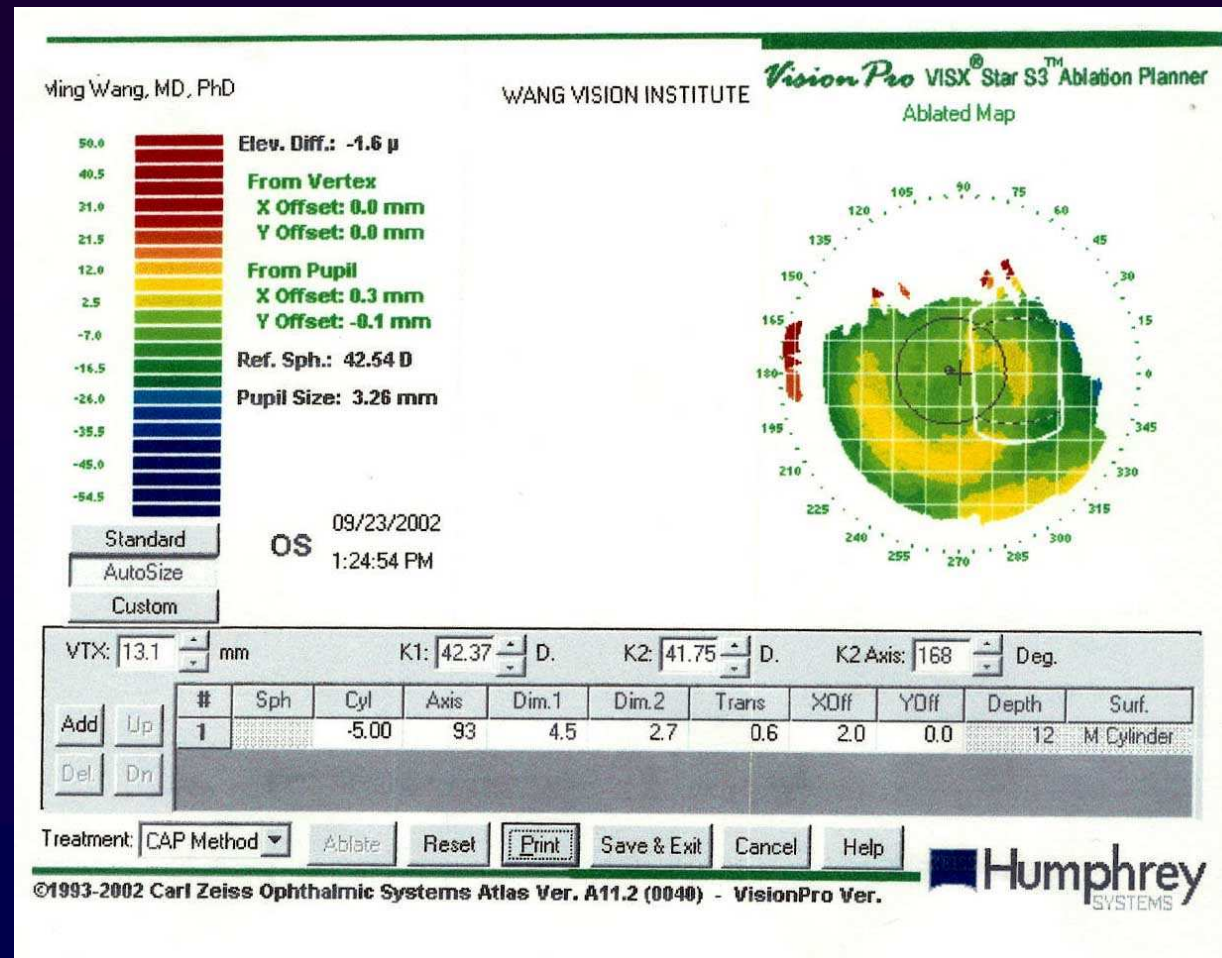


# Treatment plan (C-CAP PG)



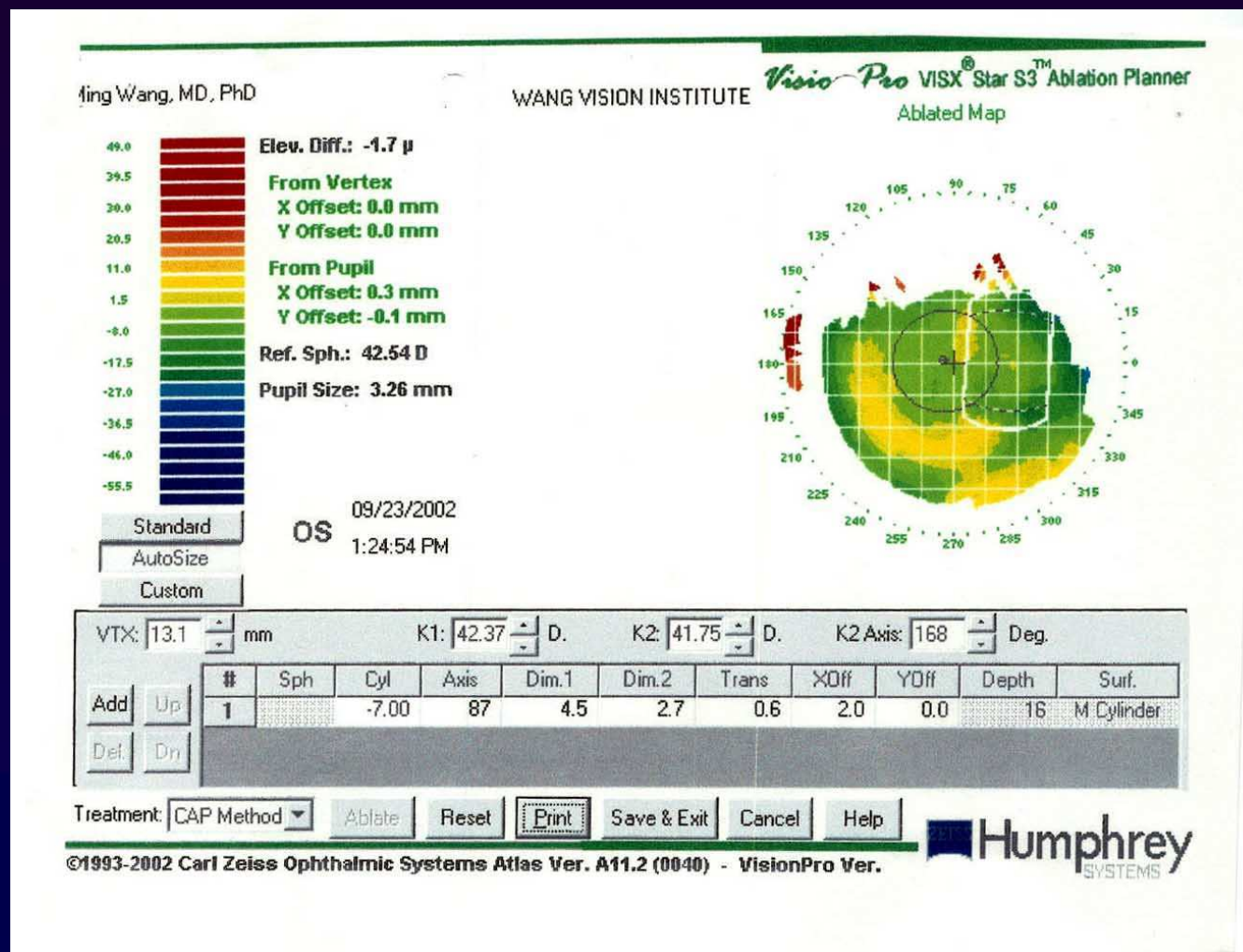


# Treatment plan (C-CAP PG)



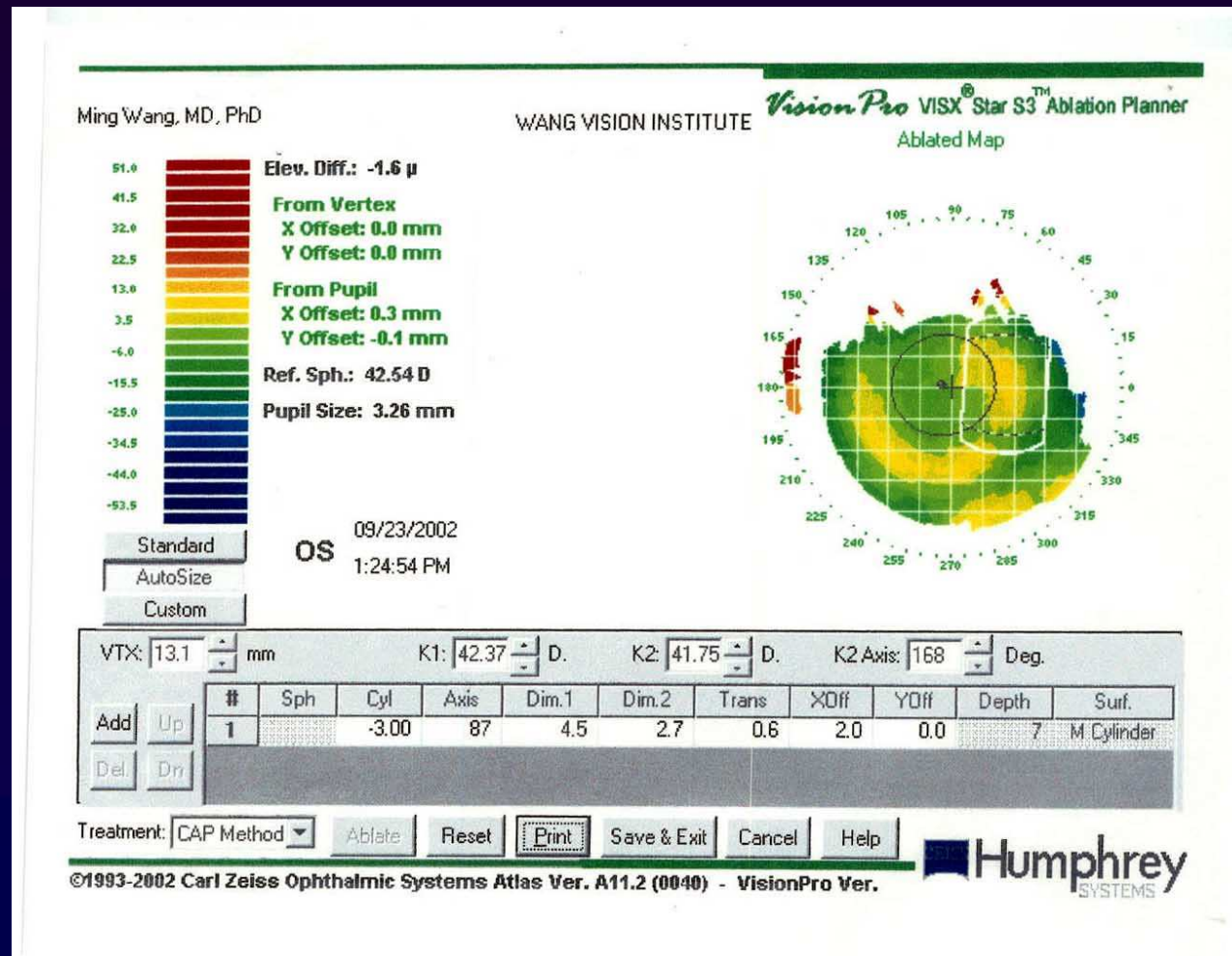


# Treatment plan (C-CAP PG)



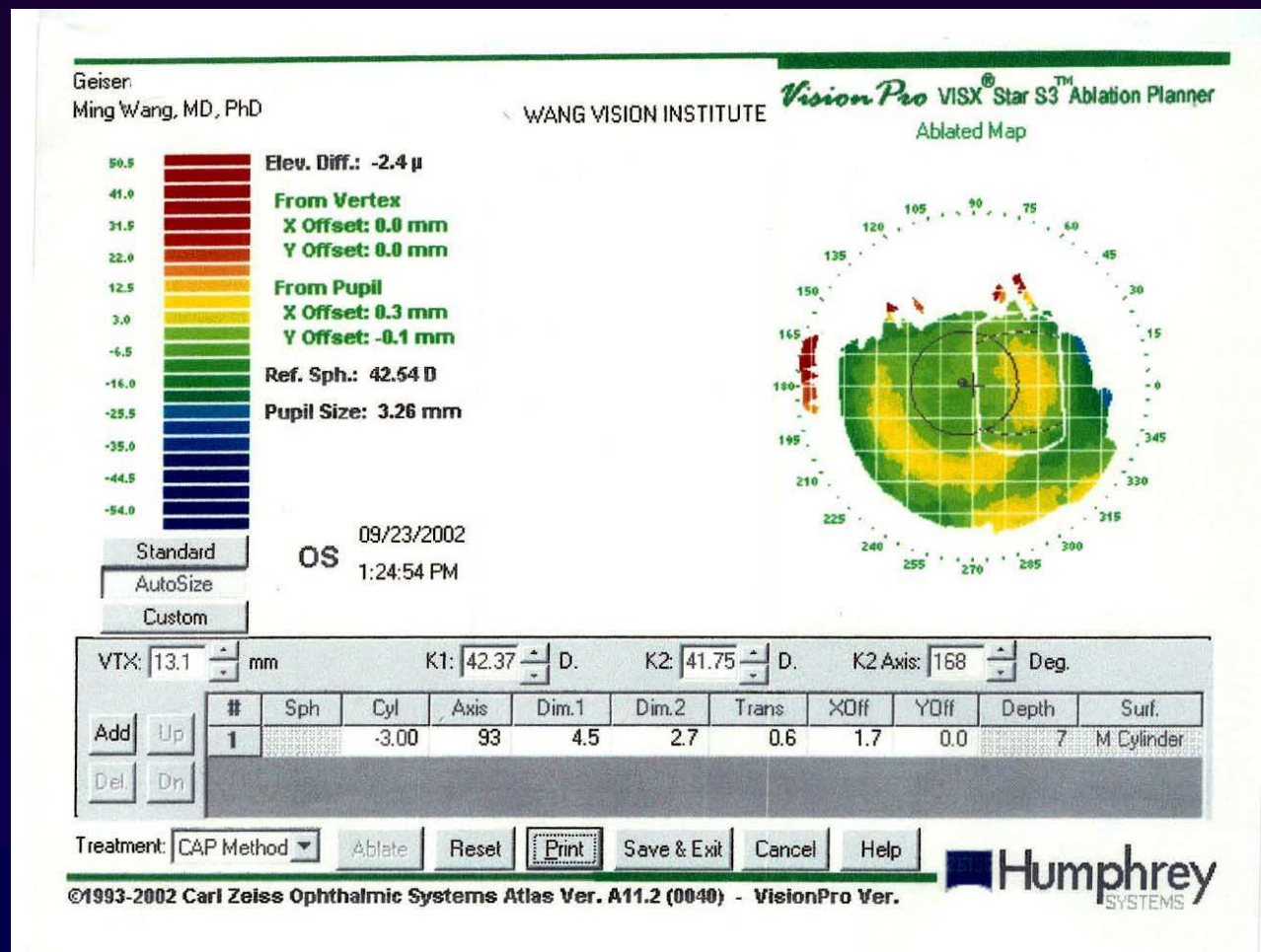


# Treatment plan (C-CAP PG)



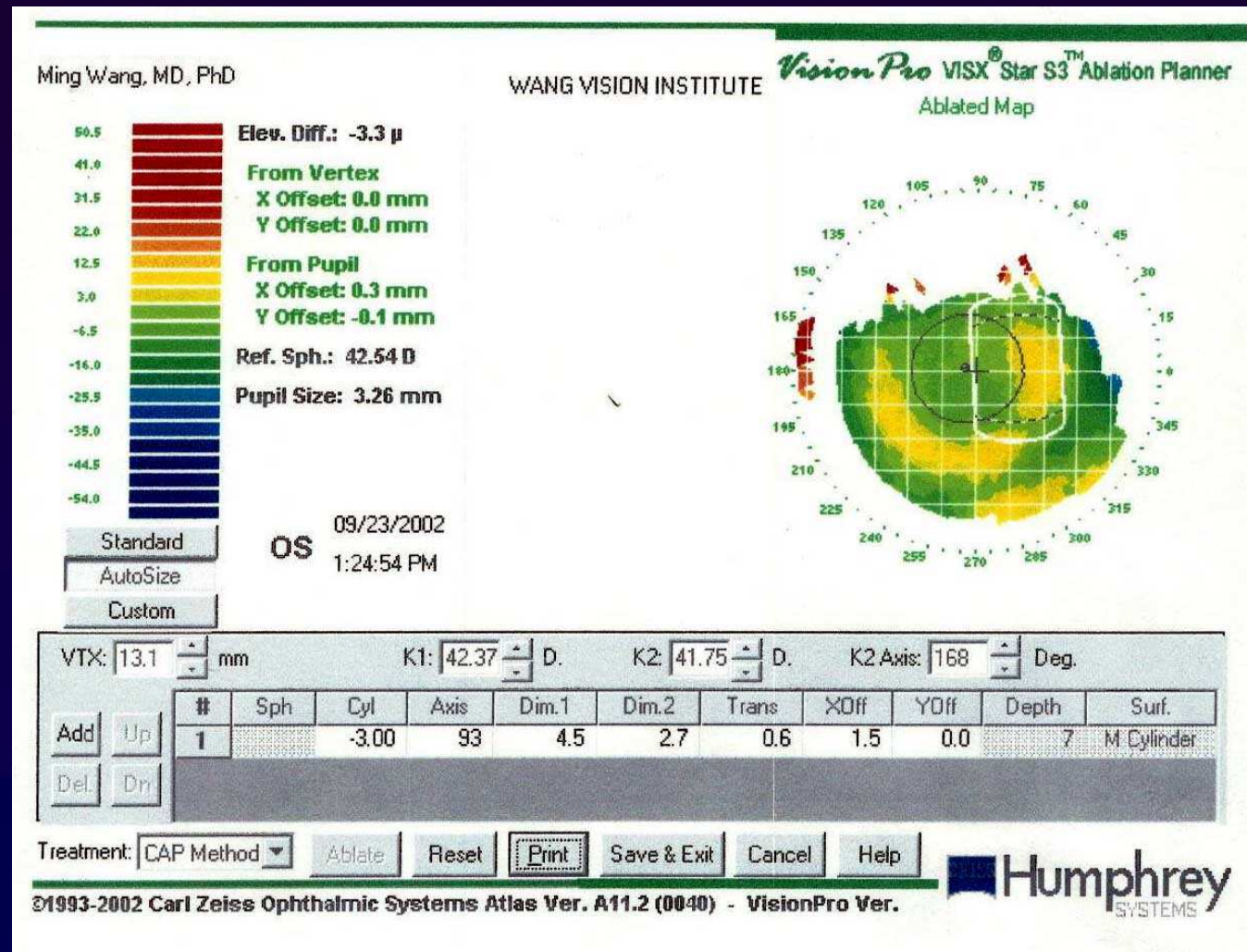


# Treatment plan (C-CAP PG)





# Final treatment plan (C-CAP PG)





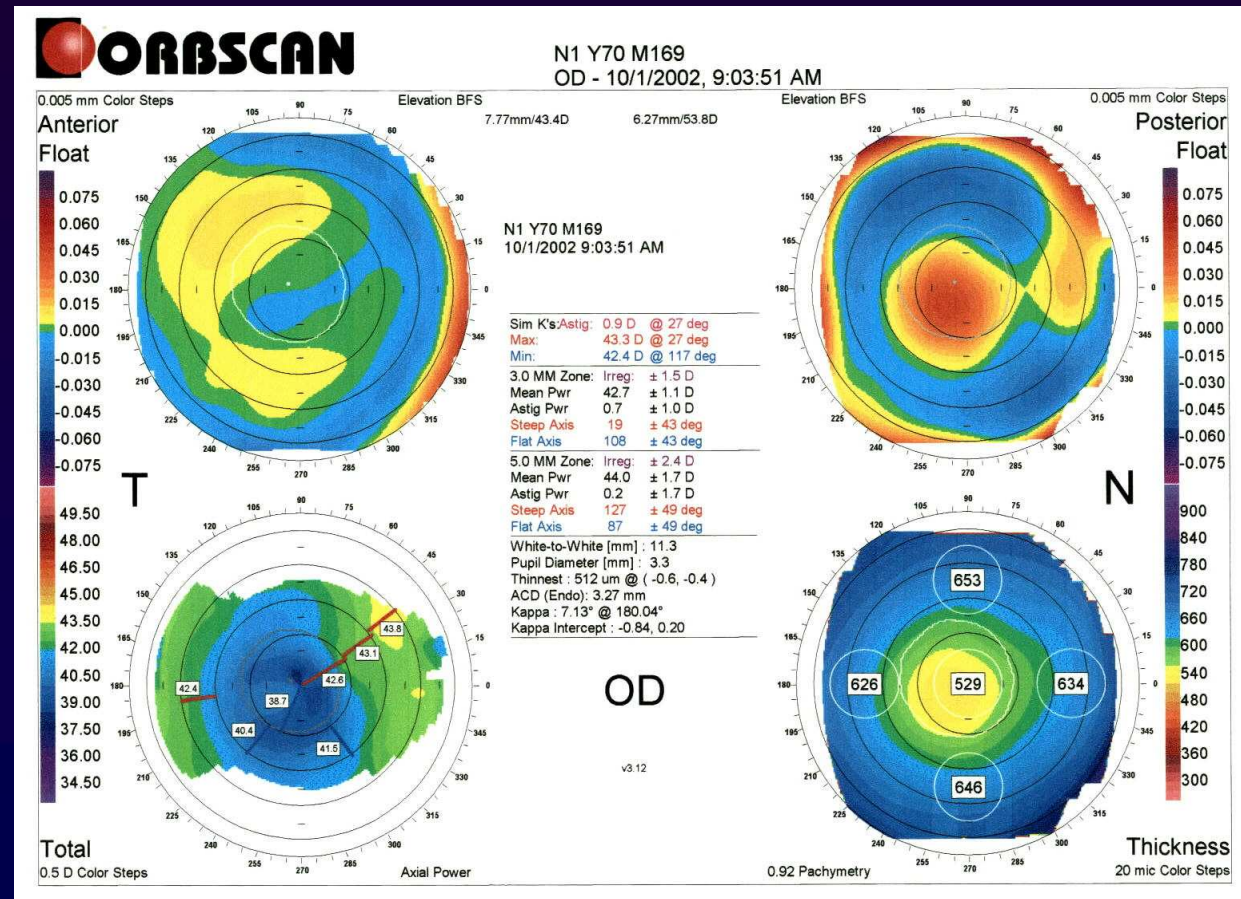
# C-CAP Case PG

- Final treatment plan:
  - M Cylinder I: 7 microns x 93 (4.5 x 2.7mm); Offsets: X +1.5 mm, Y +0.00



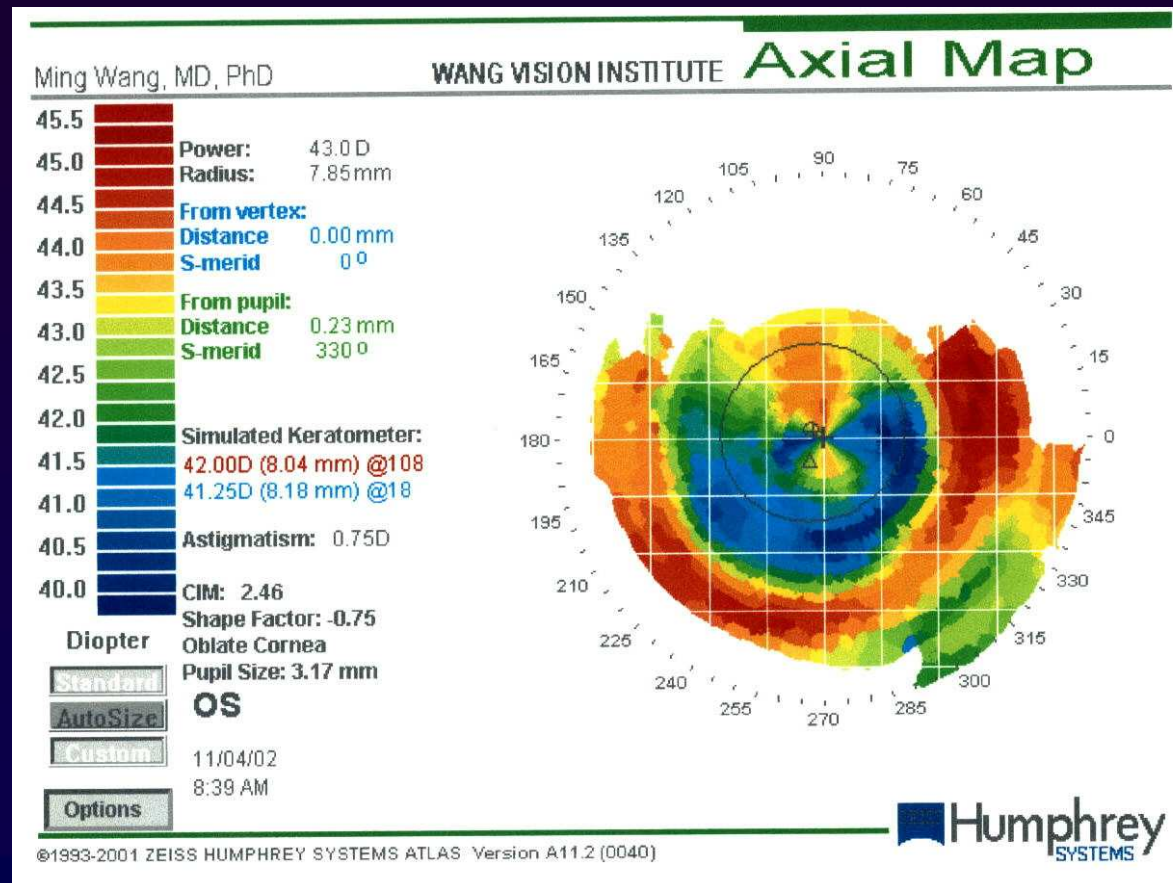
# C-CAP Case PG

- POD #1 s/p C-CAP: Felt less double vision
- VA sc 20/200



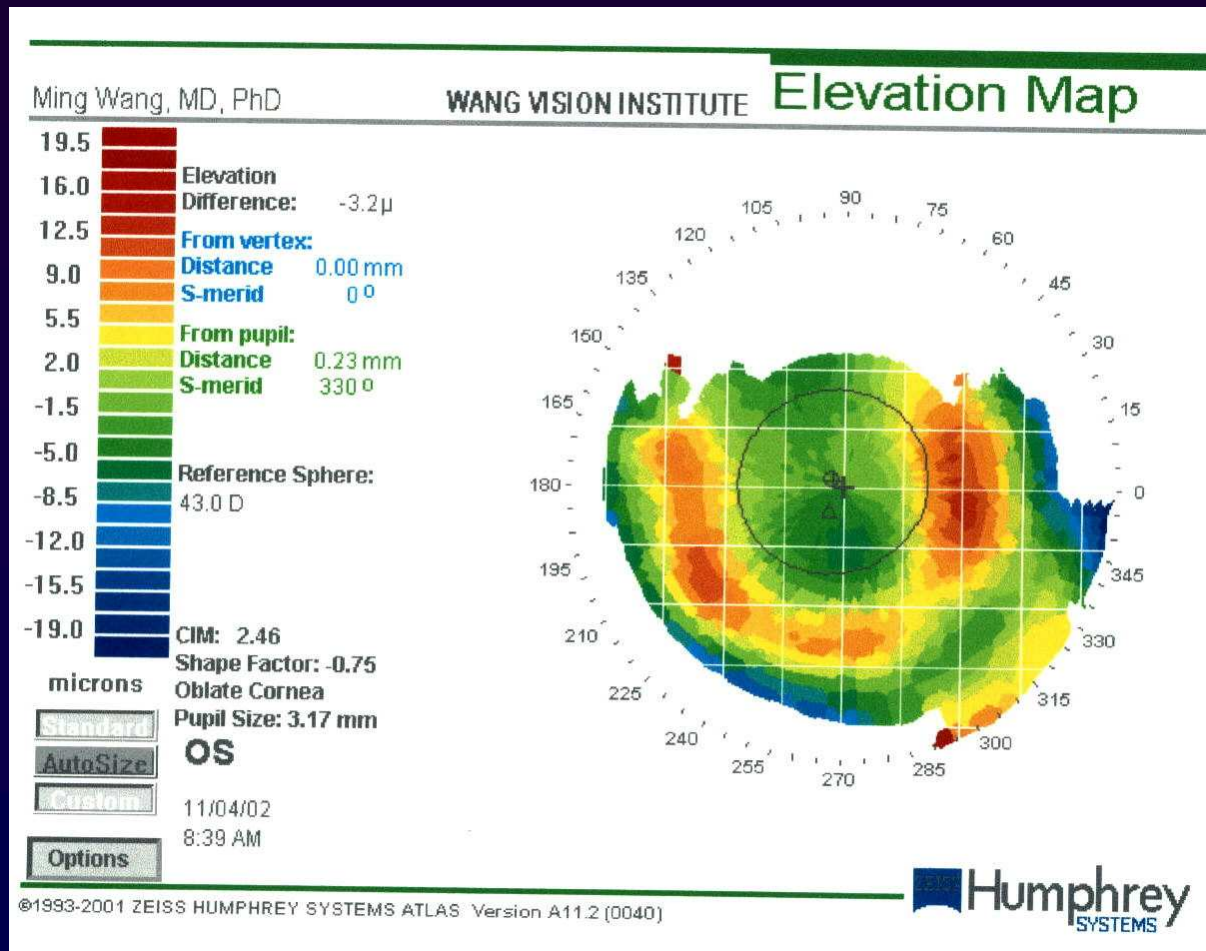


# Case PG: 1 month s/p C-CAP

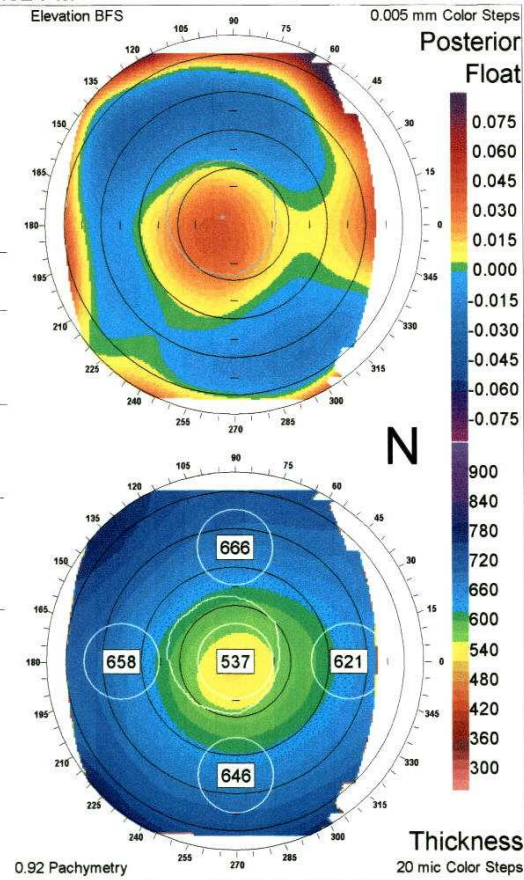




# Case PG: 1 month s/p CAP

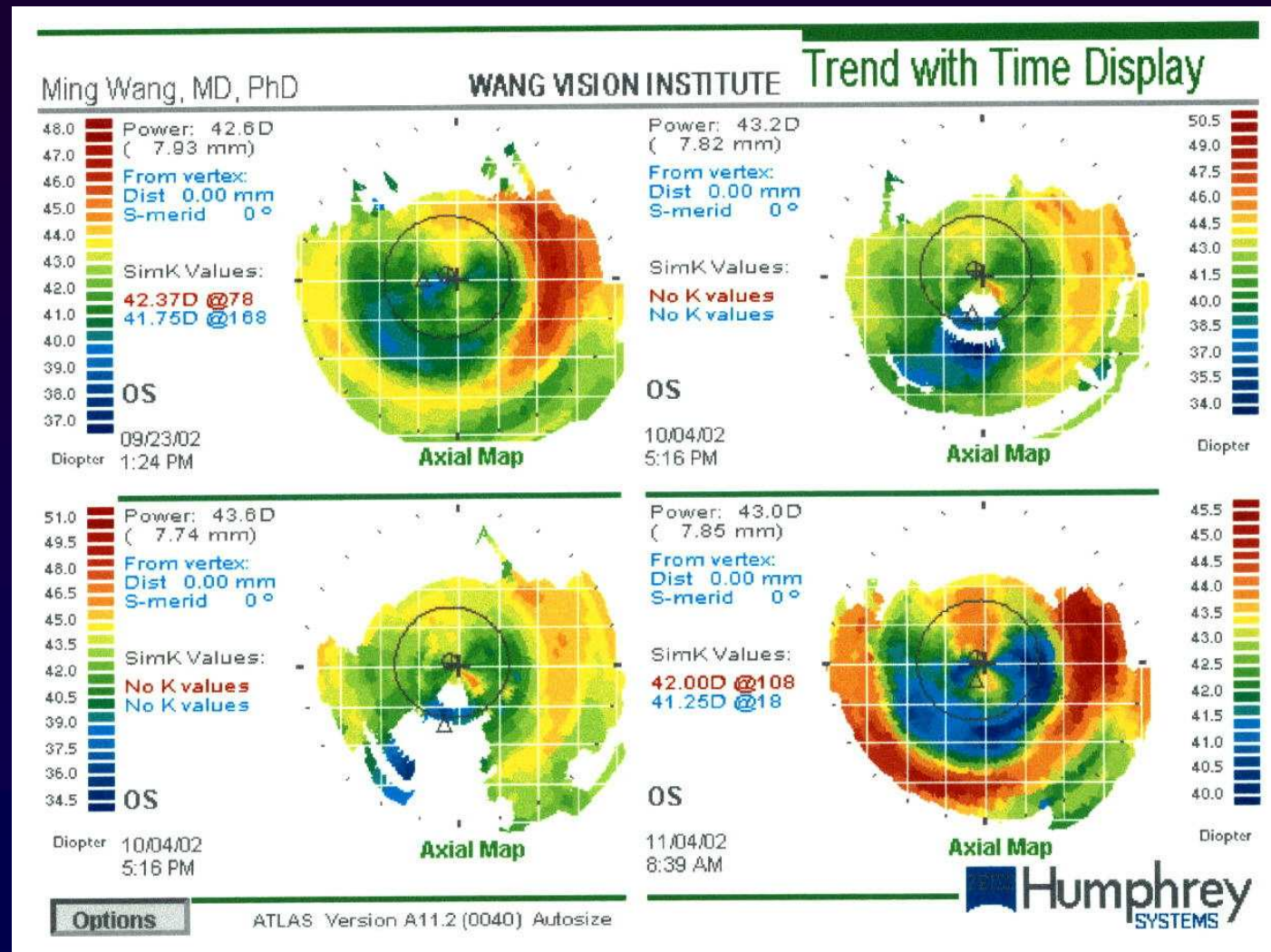








# Case PG: 2 mo Time Trend



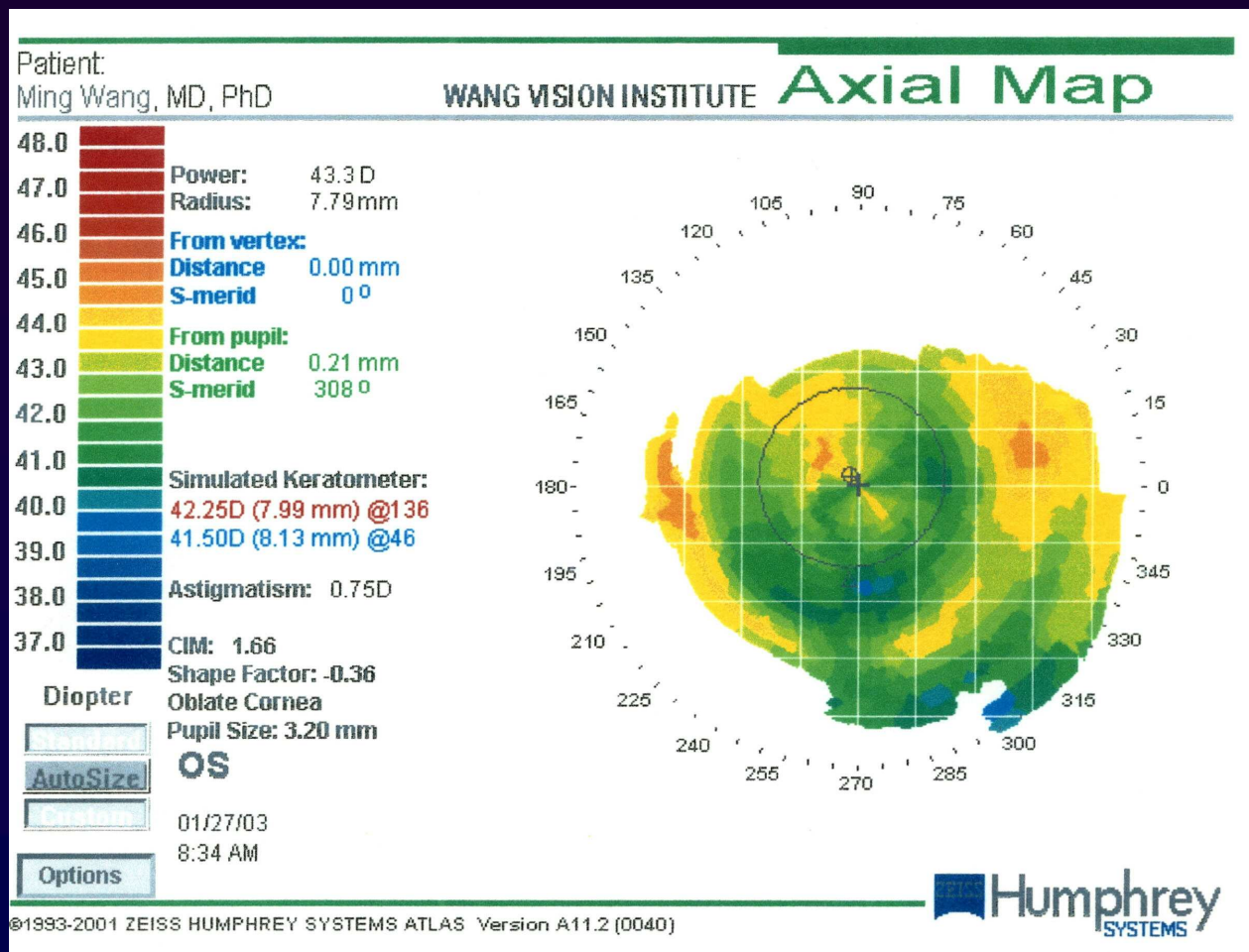


# Case PG

- Decentration regressed;
- **More aggressive** C-CAP enhancement

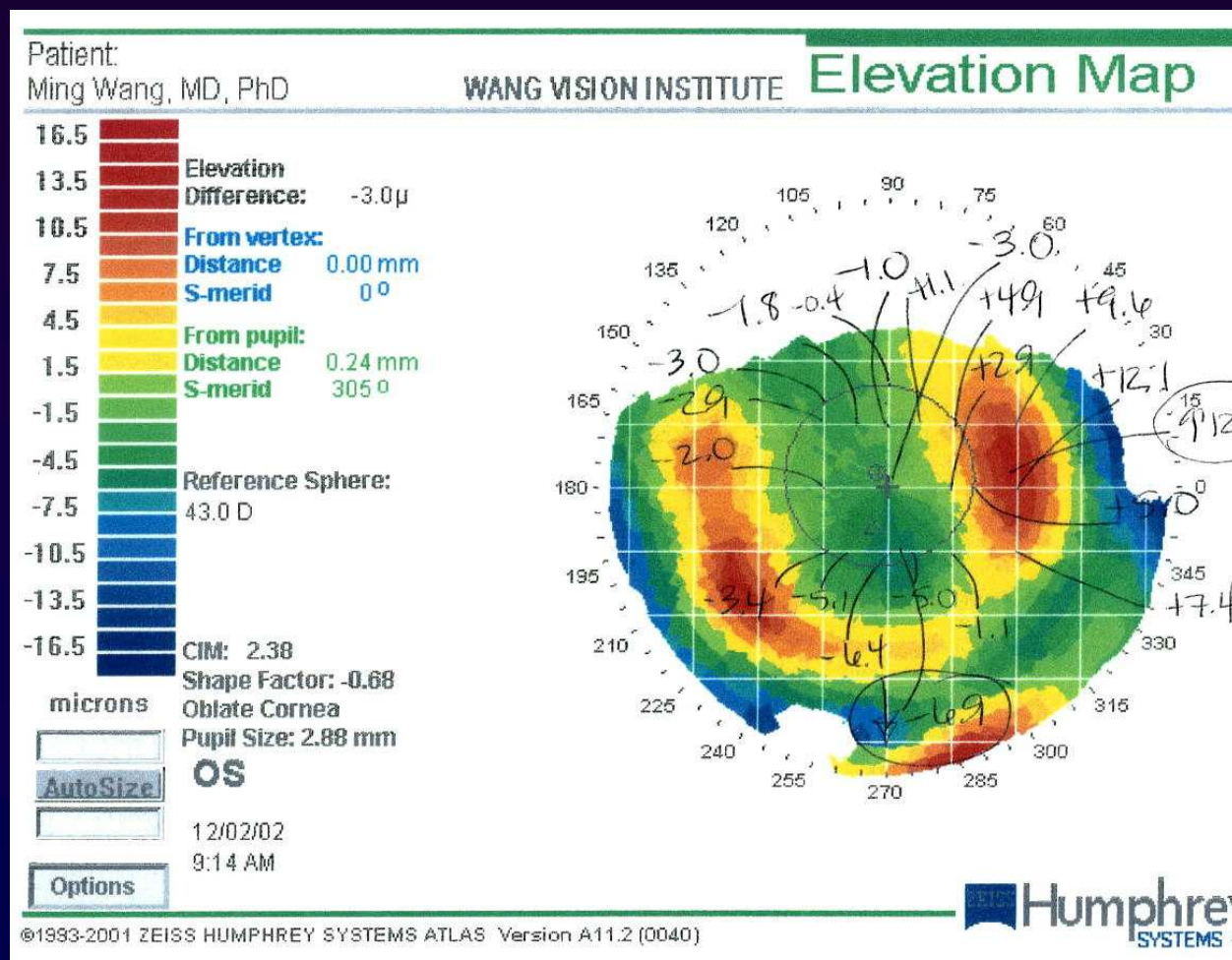


# Case PG (C-CAP enh)



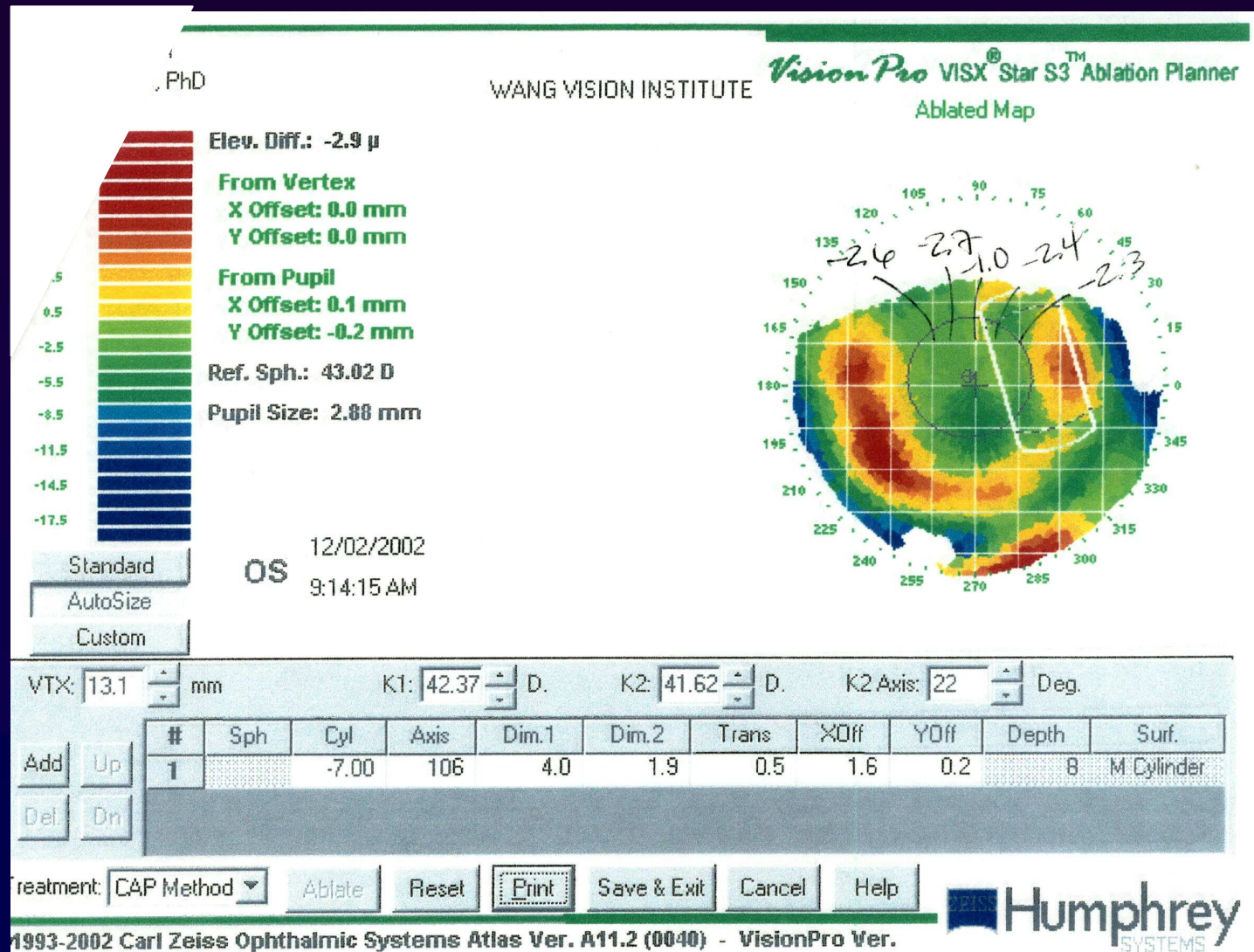


# Case PG (C-CAP enh)



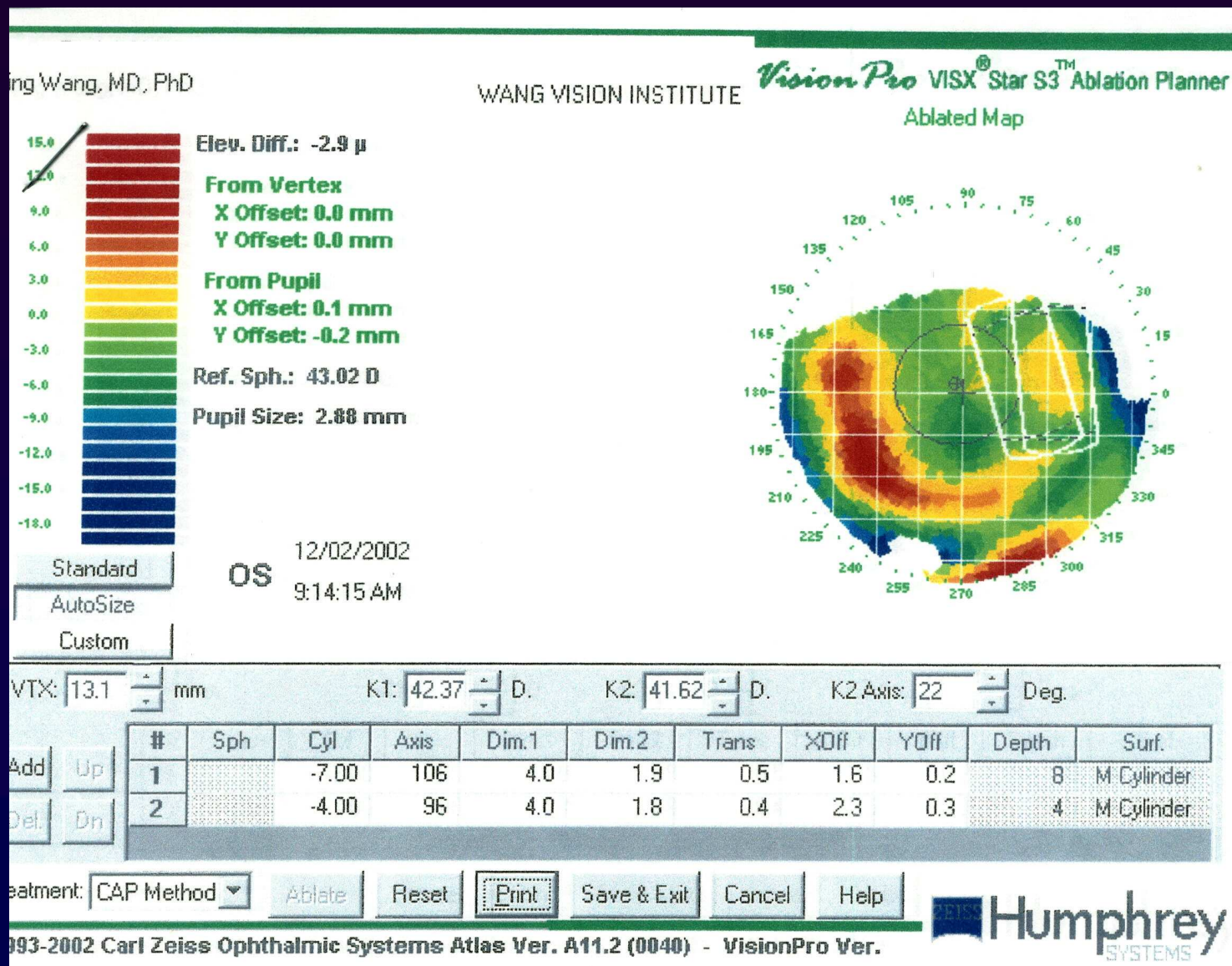


# Case PG (C-CAP enh)





# Case PG (C-CAP enh)





# Case PG (1<sup>st</sup> and 2<sup>nd</sup> C-CAP)

- First Treatment:
  - M Cylinder I: 7 microns x 93 (4.5 x 2.7mm);  
Offsets: X +1.5 mm, Y +0.00
- Second Treatment:
  - M Cylinder I: 8 microns x 106 (4.0 x 1.9mm);  
Offsets: X +1.6 mm, Y +0.2
  - M Cylinder I: 4 microns x 96 (4.0 x 1.8mm);  
Offsets: X +2.3 mm, Y +0.3



# Case PG (two C-CAPs)

POD #1: “less double vision OS”

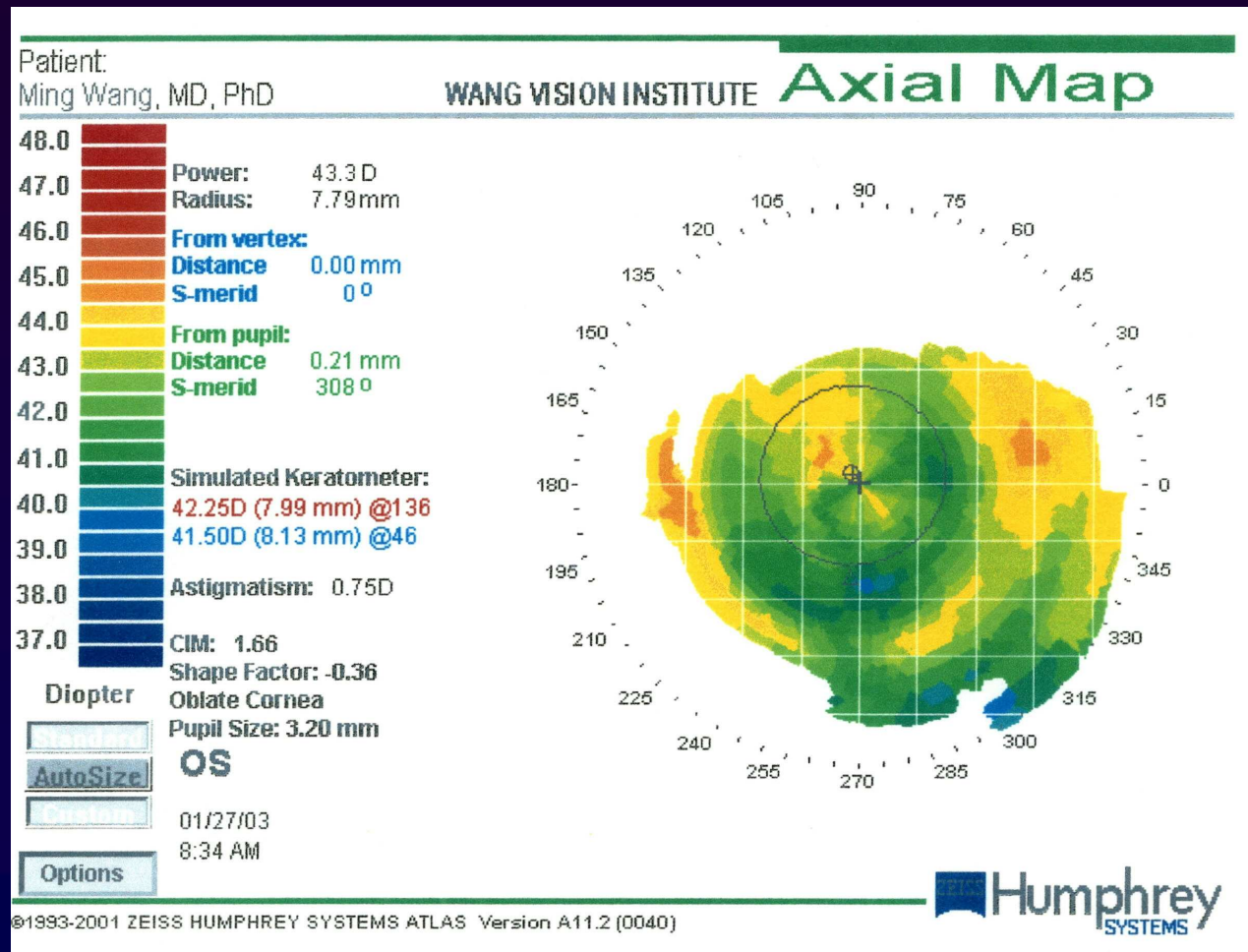
Pre-C-CAP:  $V_{sc}=20/60$ , MR  $-2.75+1.75 \times 45$ ,  
**20/30 (diplopic)**

Post-two C-CAPs:  $V_{sc} = 20/70$ , MR = -  
 $4.25+0.50 \times 110$  **20/25 (“much less” diplopic)**

Refractive treatment

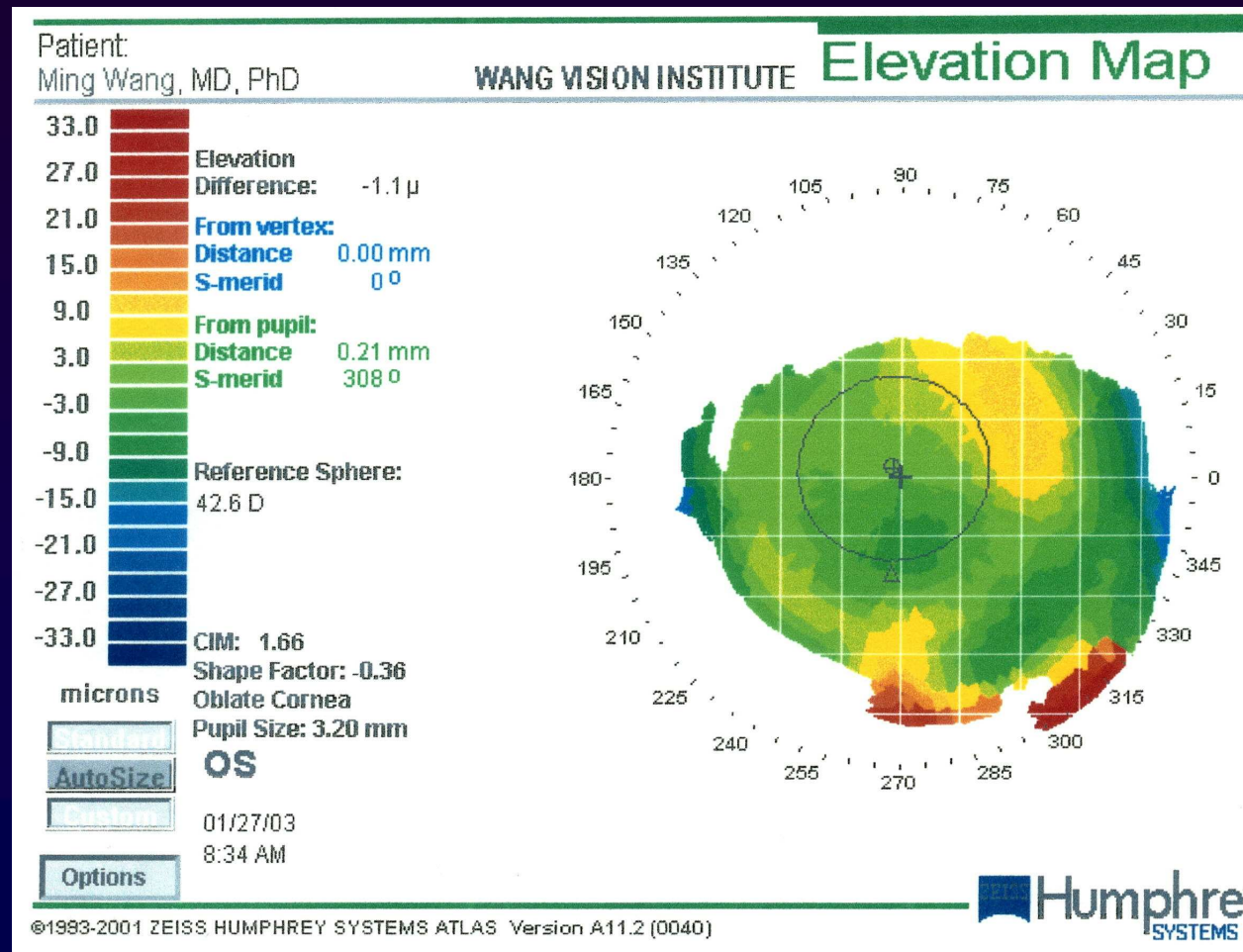


# Case PG (after two C-CAP, axial)



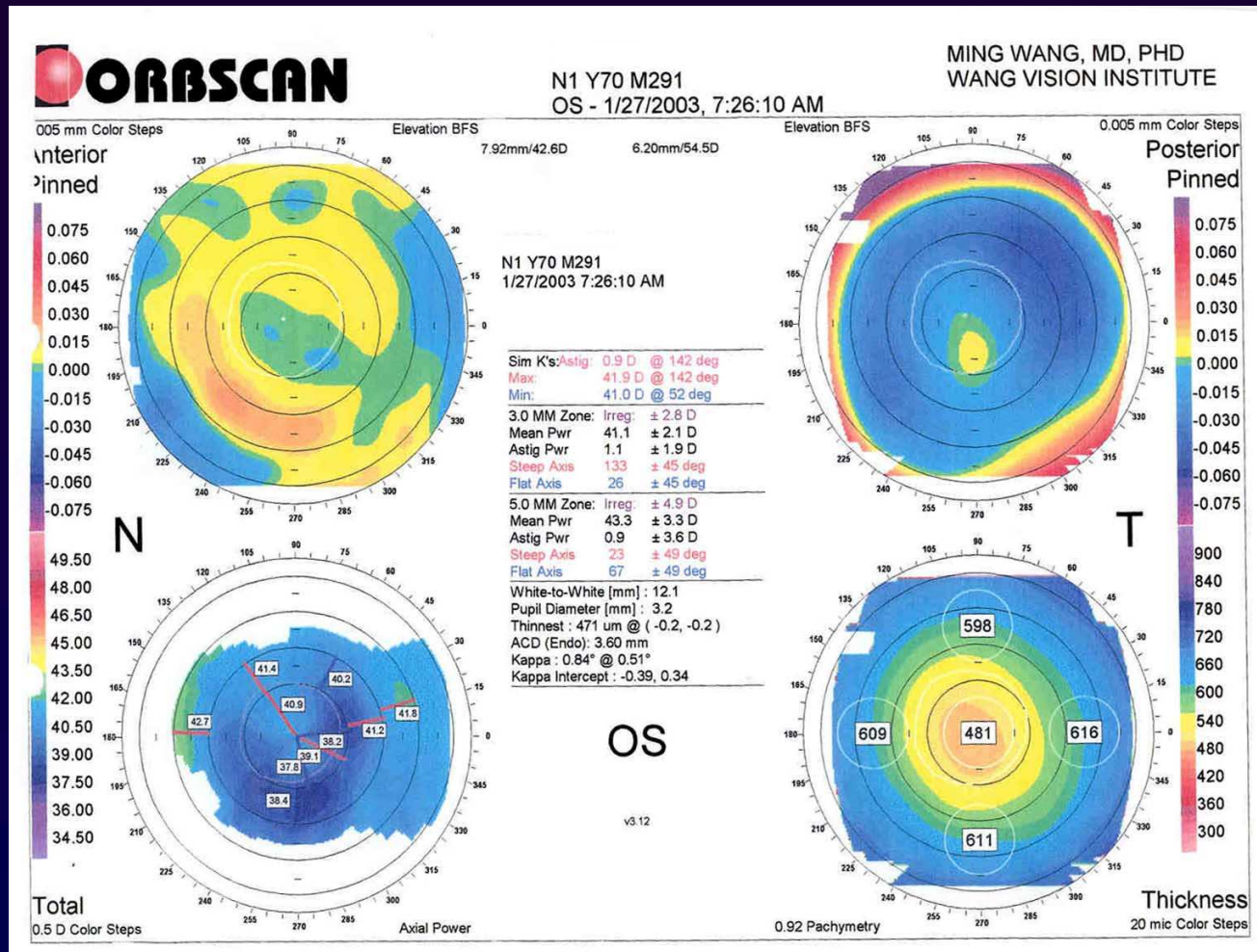


# Case PG (after two C-CAPs, elevation)





# Case PG (after two C-CAPs)





# C-CAP Case DC

- 48 yo male
- S/P myopic LASIK March 2002 followed by **hyperopic** LASIK-E OD June 2002 by area surgeon
- Complains of blurred vision even with glasses OD ever since the enhancement



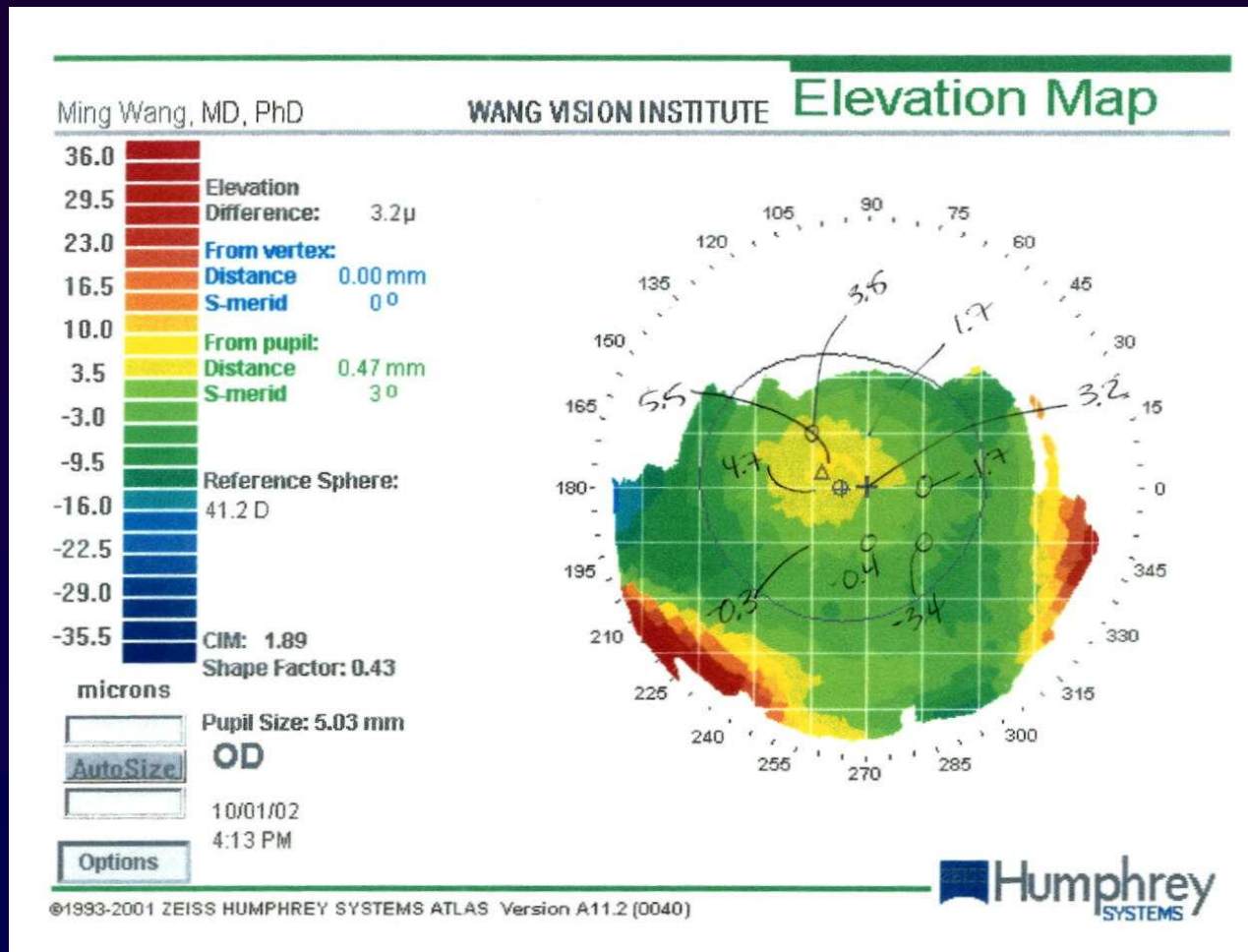
# C-CAP Case DC

- Unaided VA: 20/30-
- MR  $-0.50+2.00 \times 11$  (20/25-, blurred)
- Cyclo  $-0.25+2.00 \times 11$  (20/25-, blurred)
- RGP VA 20/20 (not blurred)
- Ultrasound Pachy 503 microns



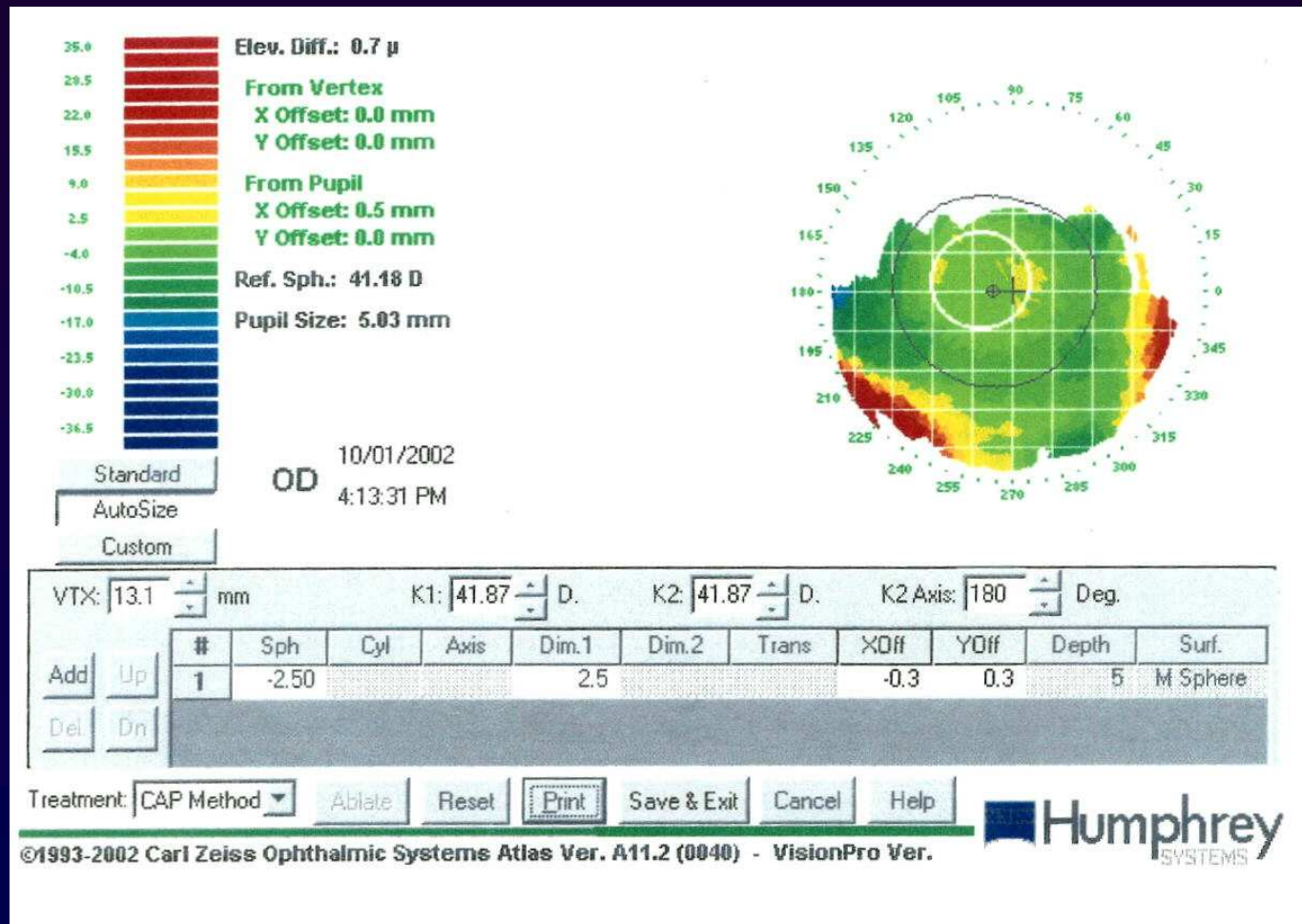
# Elevation map with height values

## C-CAP Case DC (s/p HL)



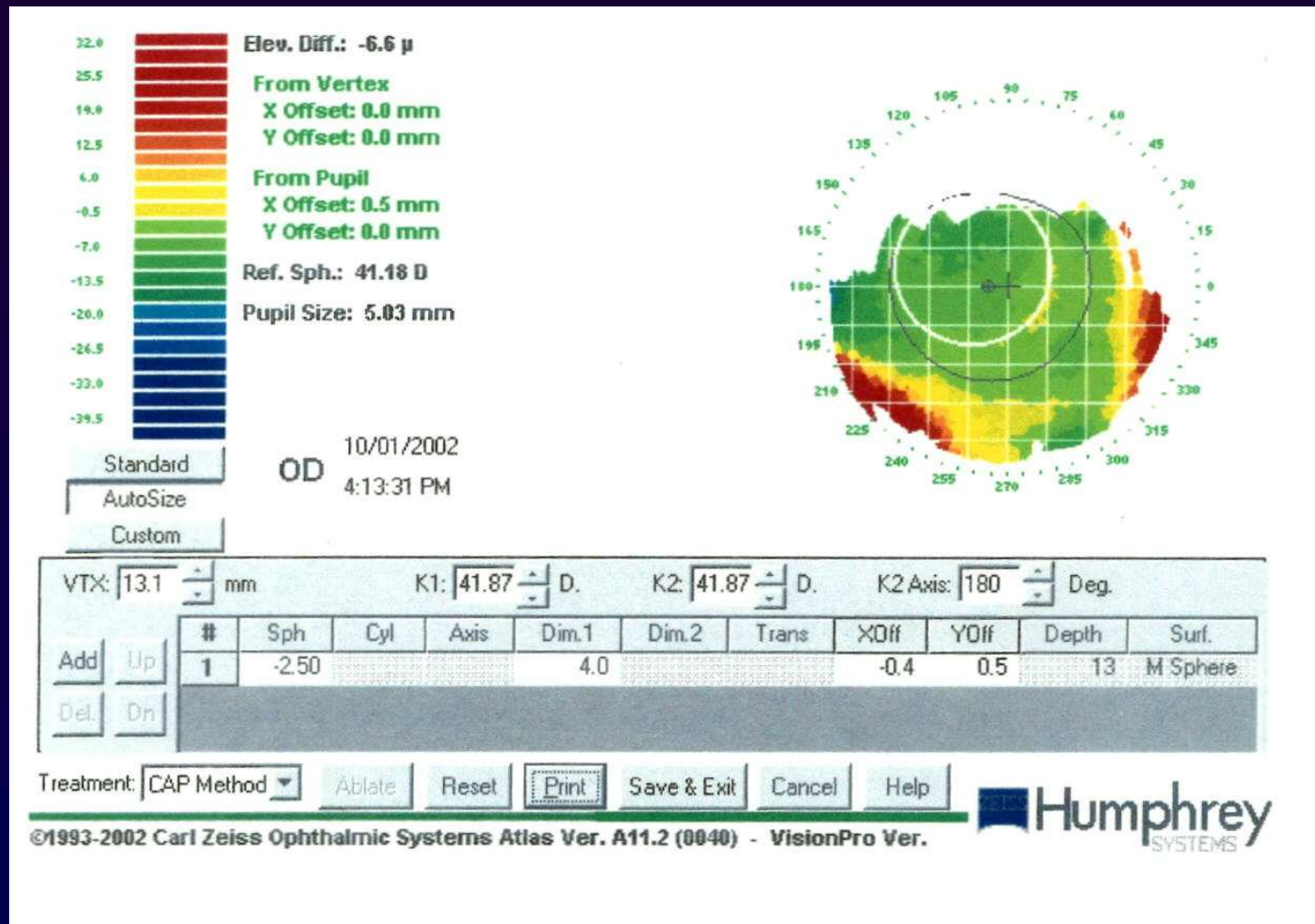


# Treatment plan (C-CAP DC)



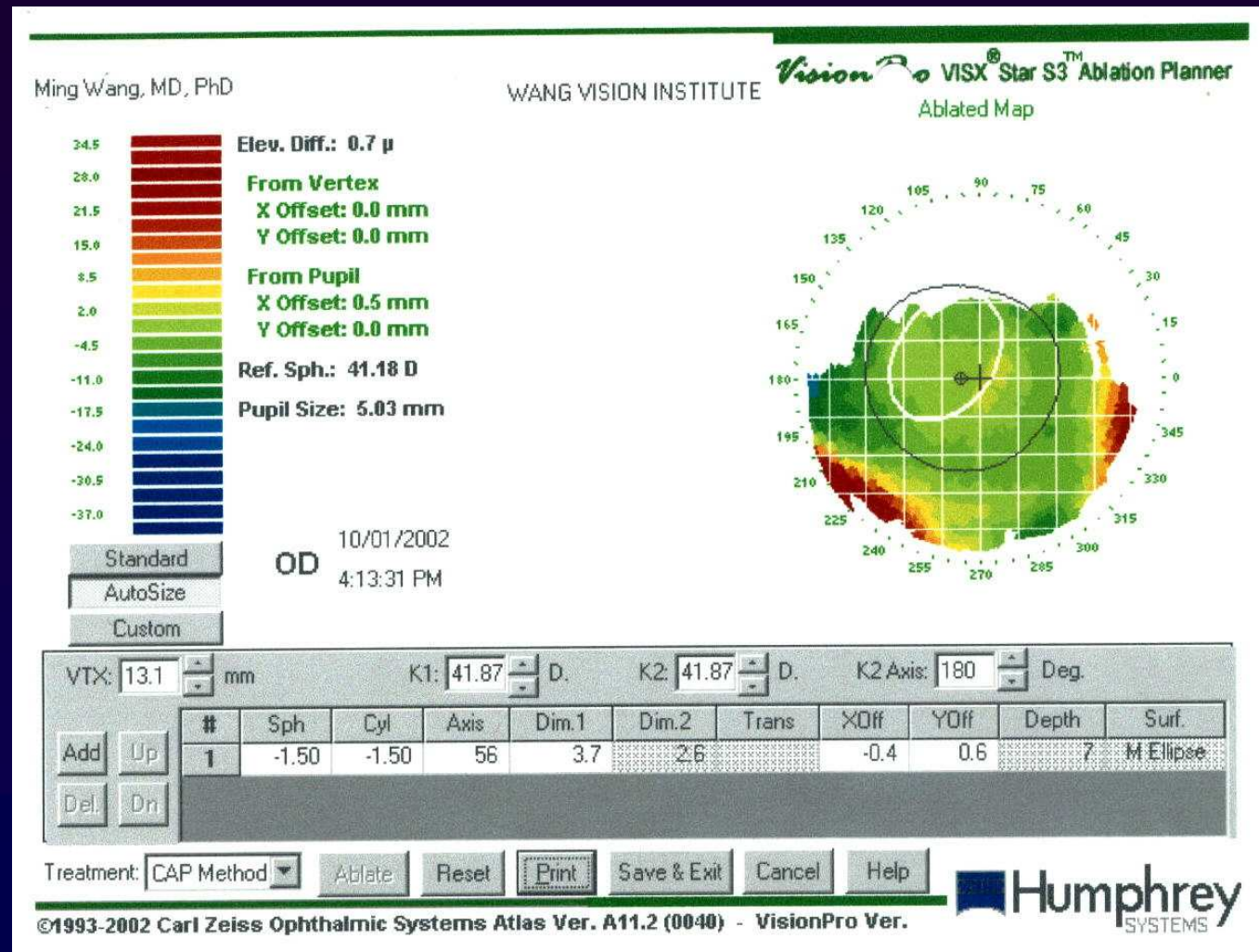


# C-CAP Treatment plan (DC)



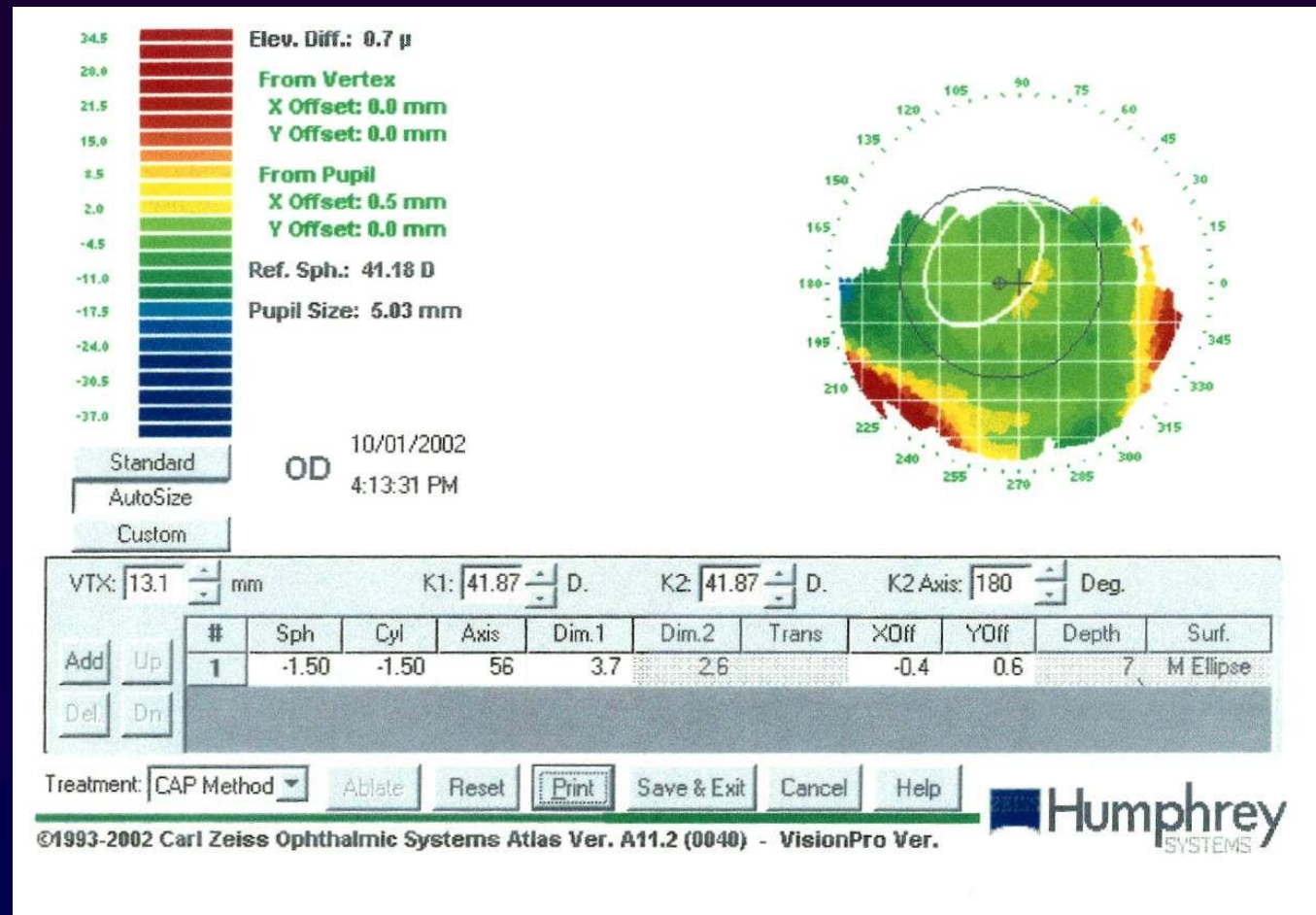


# Treatment plan (C-CAP DC)





# Final treatment plan (C-CAP DC)





# Final treatment plan

- Final C-CAP treatment plan:
  - M Cylinder I: 7 microns x 56 (3.7 x 3.6mm); Offsets: X -0.4 mm, Y 0.6mm



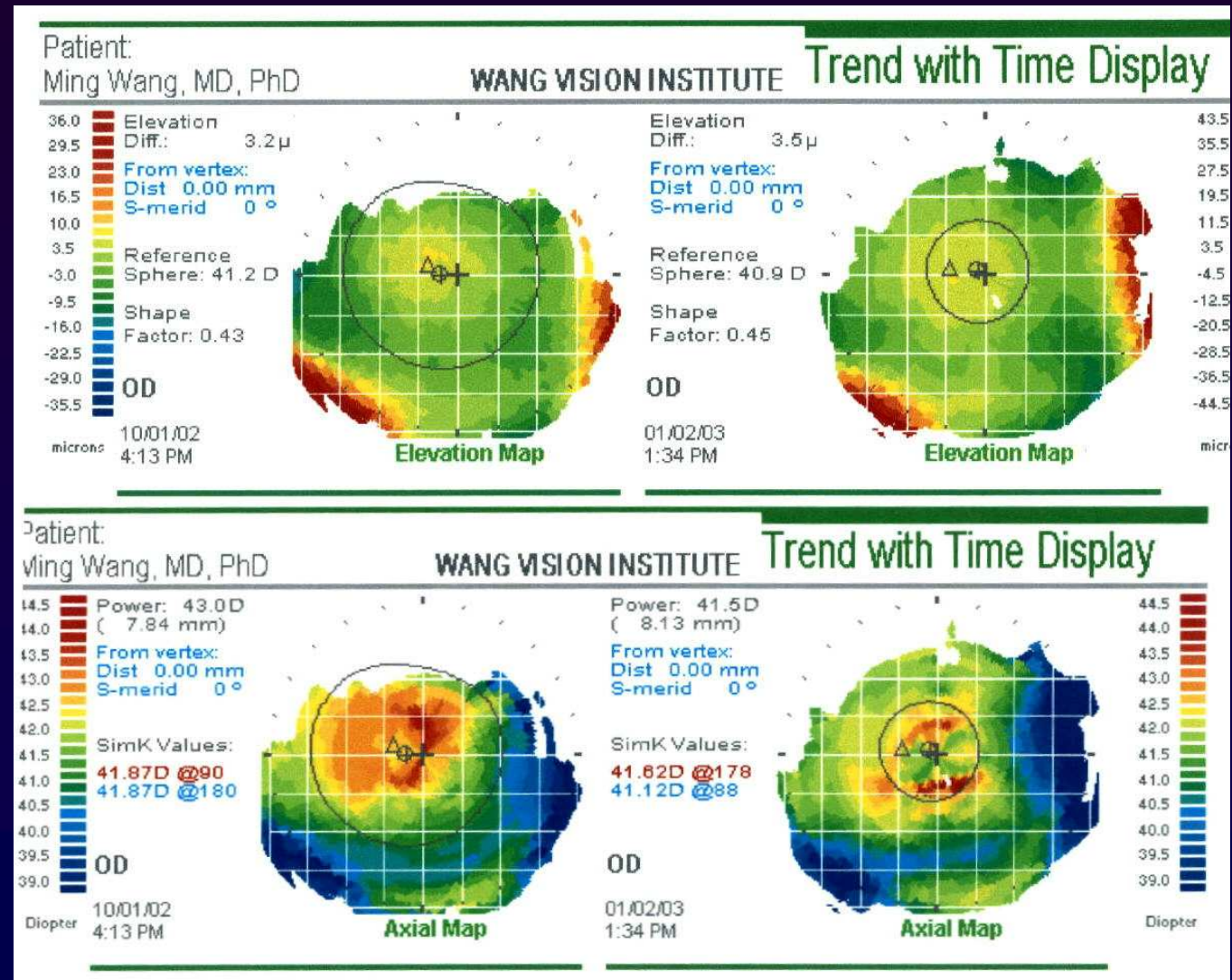
# C-CAP Case DC (s/p HL)

- POD #1
  - CC: “Doing well”
  - VA sc 20/30
- 3 mo PO
  - Unaided VA: 20/70
  - Symptoms of distortion resolved
  - MR  $-1.00+1.00$  x 40, 20/25+ (**bluriness 90% gone**)
  - Patient requests refractive enhancement



# Case DC: 3 mo s/p C-CAP

- Patient requested refractive enhancement at three months after C-CAP
- Vsc = 20/25  
POD #1  
After refractive treatment





Cautionary note #1 on C-CAP:  
Always look at the **elevation** map at  
the end

- JJ presented with distance vision complaints  
OS after having LASIK by an area surgeon
- POHx:
  - H-LASIK OS 11/99
  - LASIK enh 4/01
  - CE with IOL 3/02
  - Myopic astigmatism LASIK 7/02

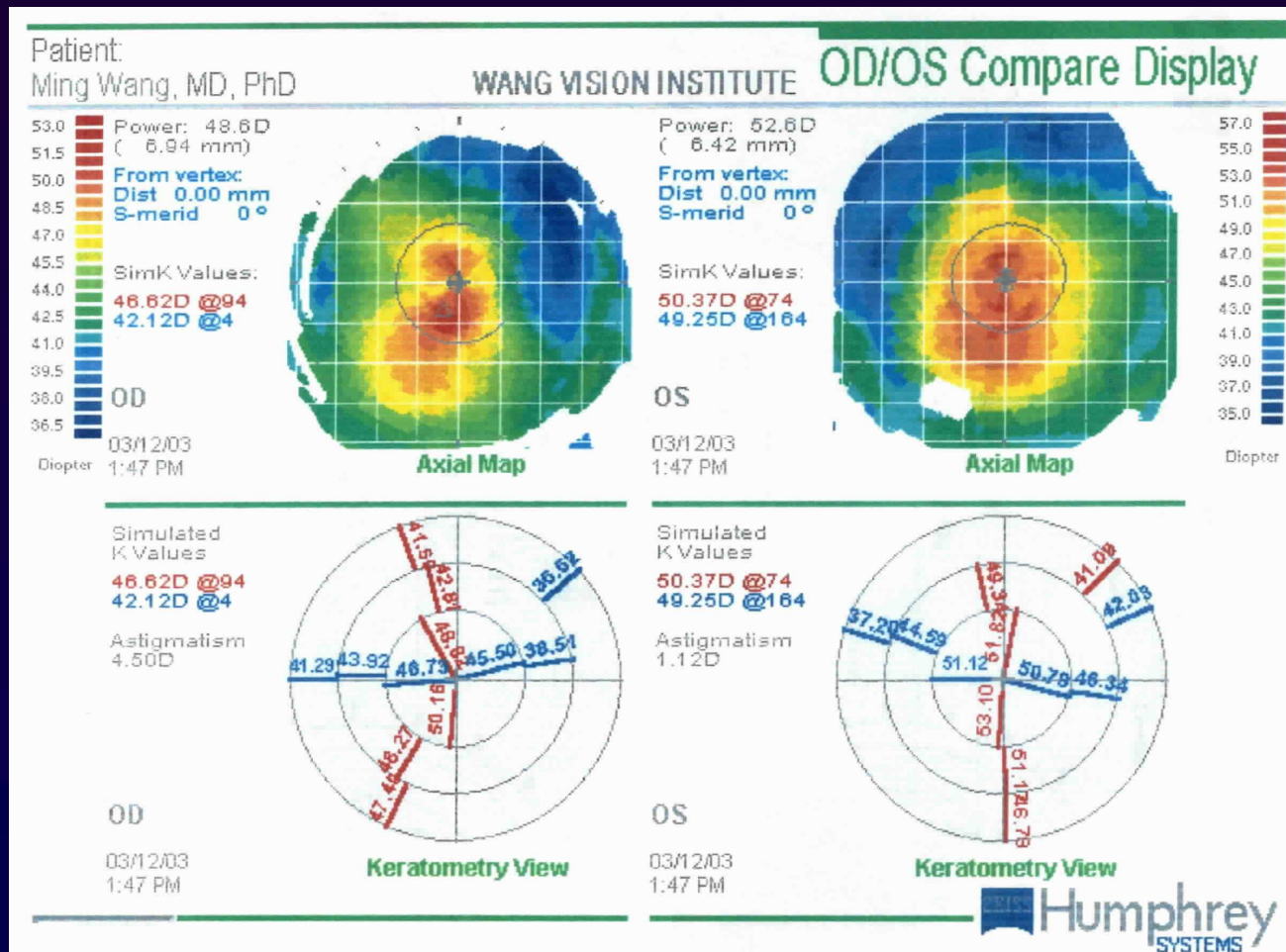


# Case JJ: Always look at **elevation** map

- MR OS -4.00+2.25 x 110, 20/100
- PH 20/40
- RGP OR VA 20/30\*\*\*

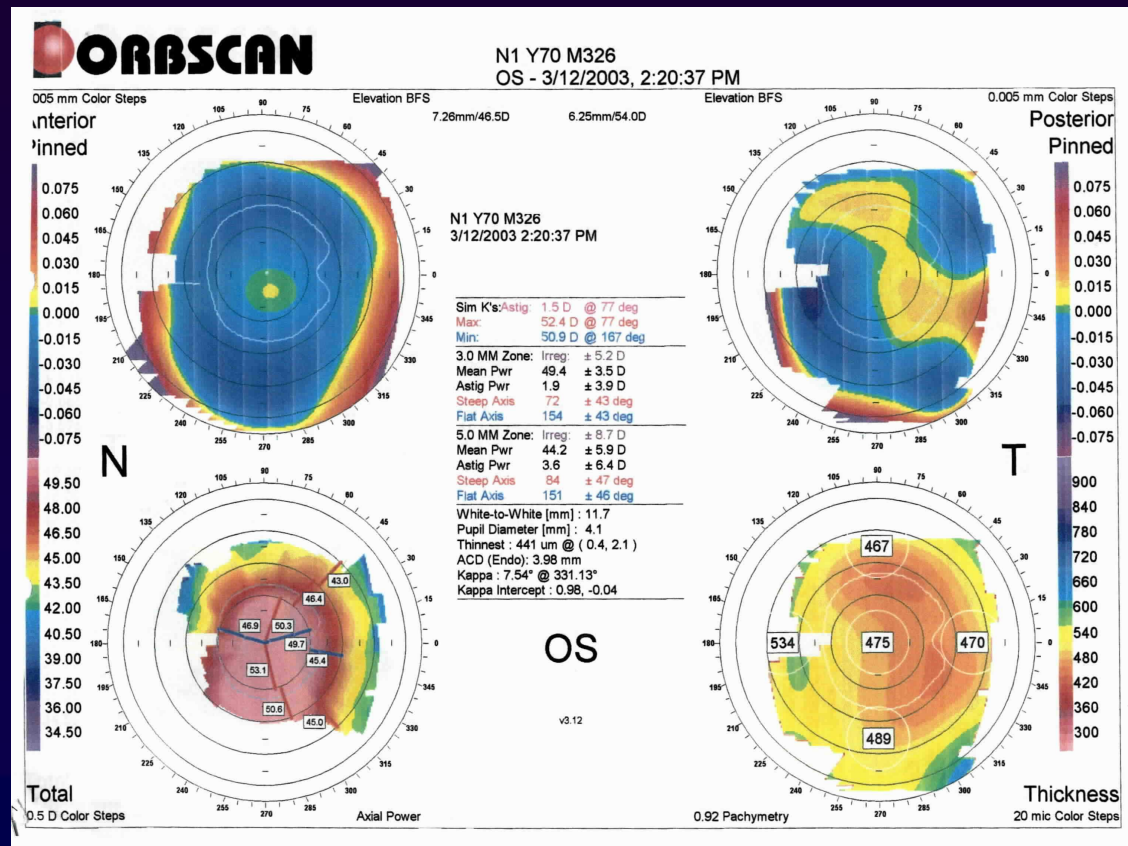


# Case JJ: Axial maps (OS, appeared to be inferiorly decentered)



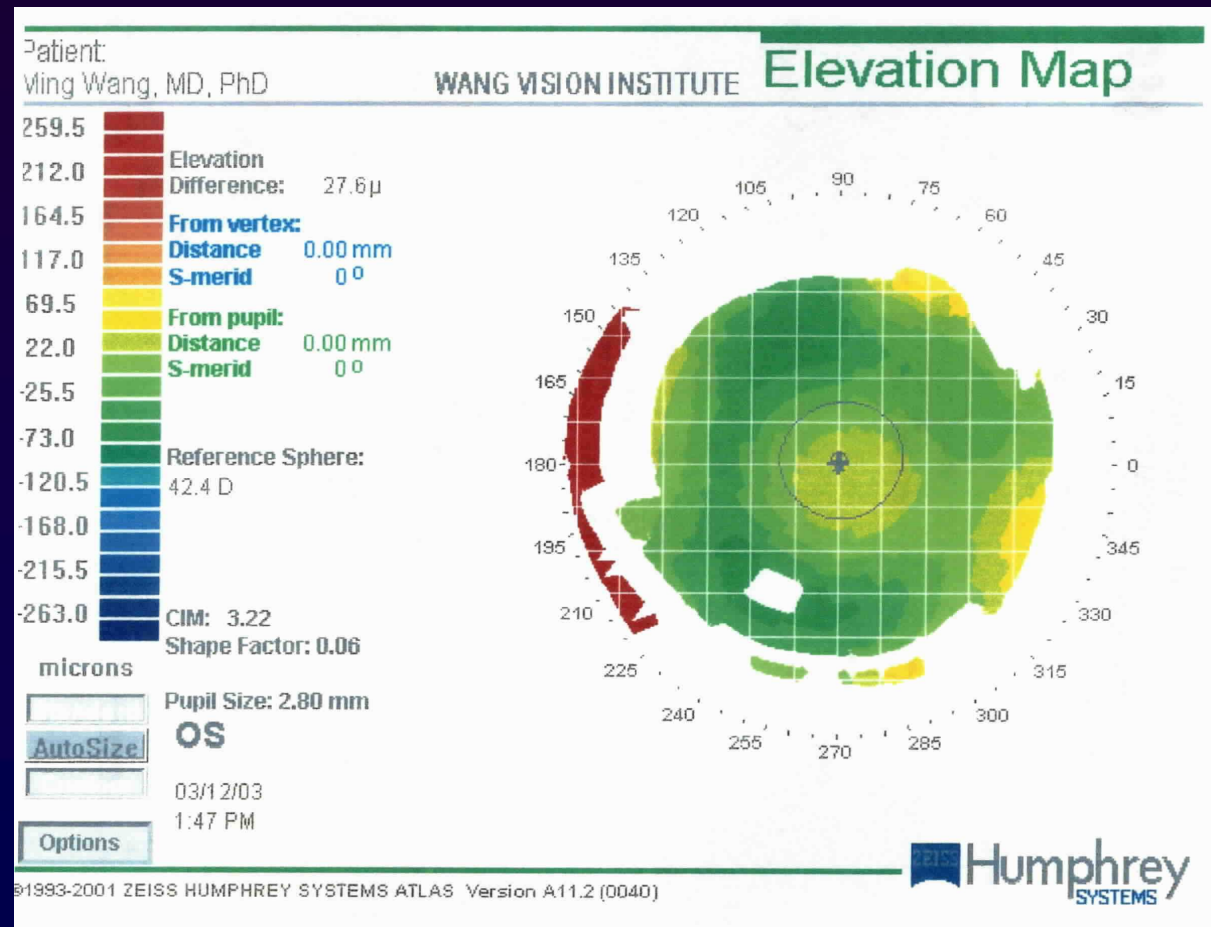


# Case JJ: Axial maps (OS, inferior decentration)





# Case JJ: Elevation map (OS no significant decentration, so no C-CAP is needed)



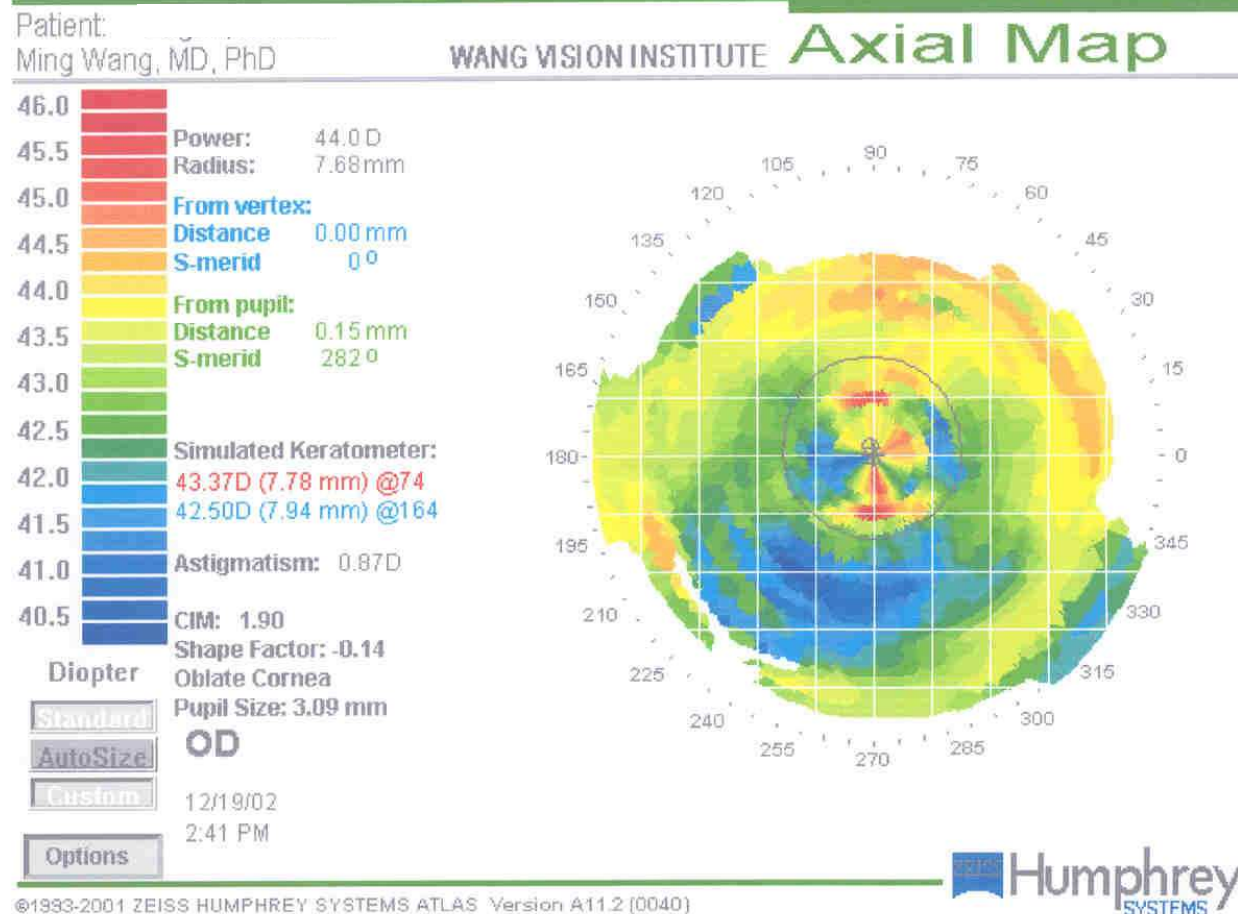


Cautionary note #2 on C-CAP: need to wait for decentration to stabilize, with full medical therapy, before doing any surgery such as C-CAP (ML)

- Patient presented with complaints of visual distortion and poor visual quality OD after LASIK in October 2002
- VA sc 20/60
- MR OD  $-2.00+1.00 \times 102$  20/40 (blurry)
- Cyclo  $-1.75+0.75 \times 105$  20/30 (blurry)

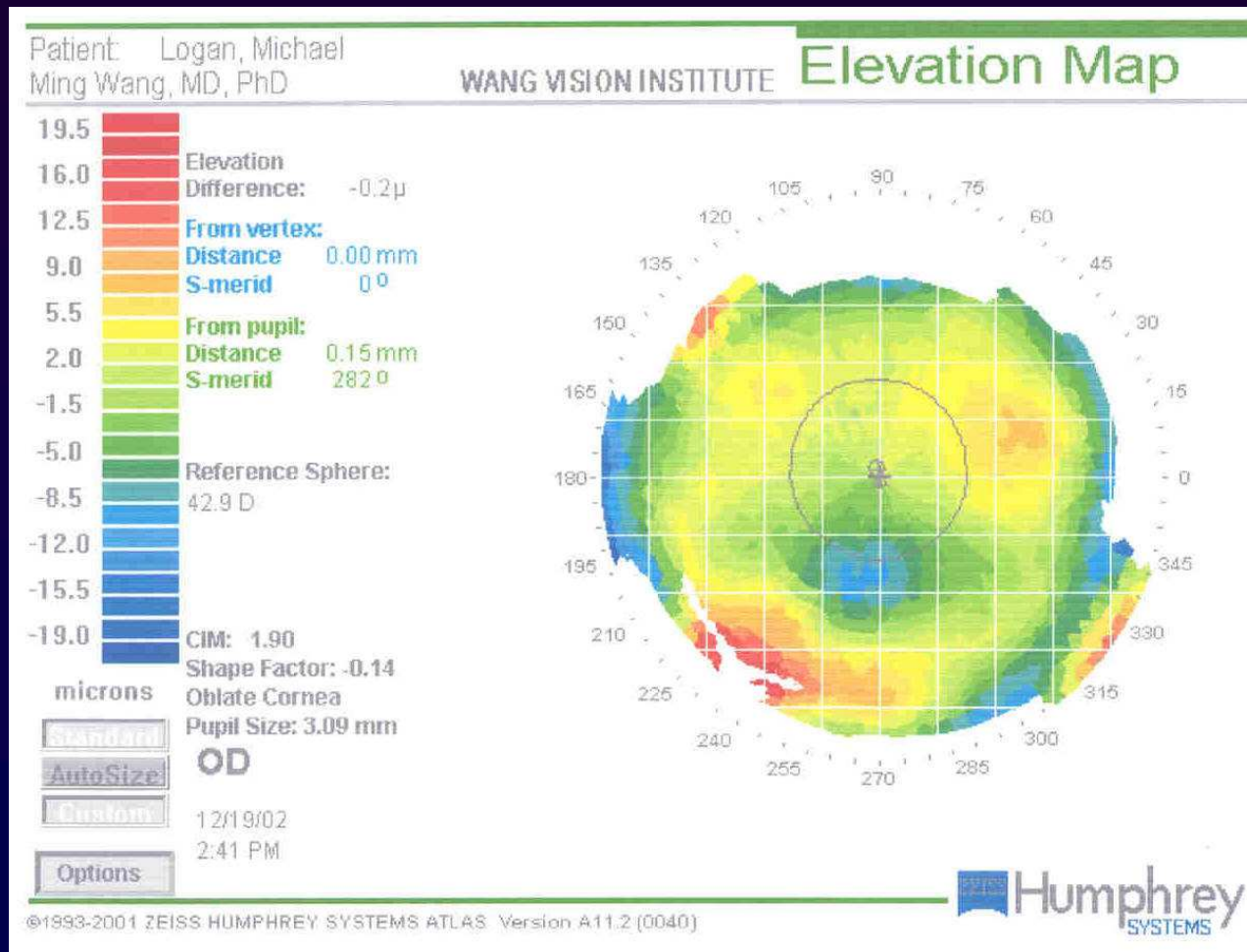


# Case ML: Decentration





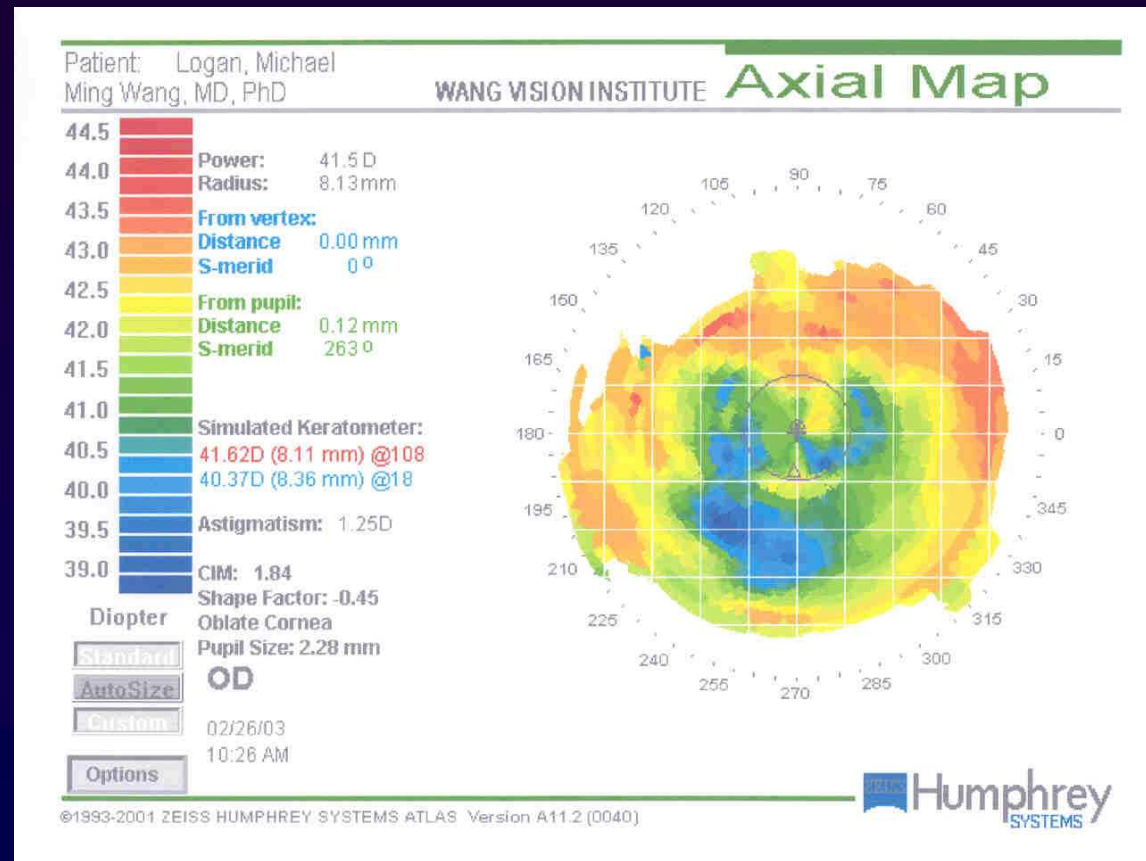
# Case ML: Decentered myopic LASIK (elevation map)





# Case ML: Self resolution of decentration

- DES: plugged RLL;
- FU 6 wks later
- MR -1.50 +0.50x125  
20/25+ (improved!)
  - Decentration is improving
  - Dry eye has improved OD;



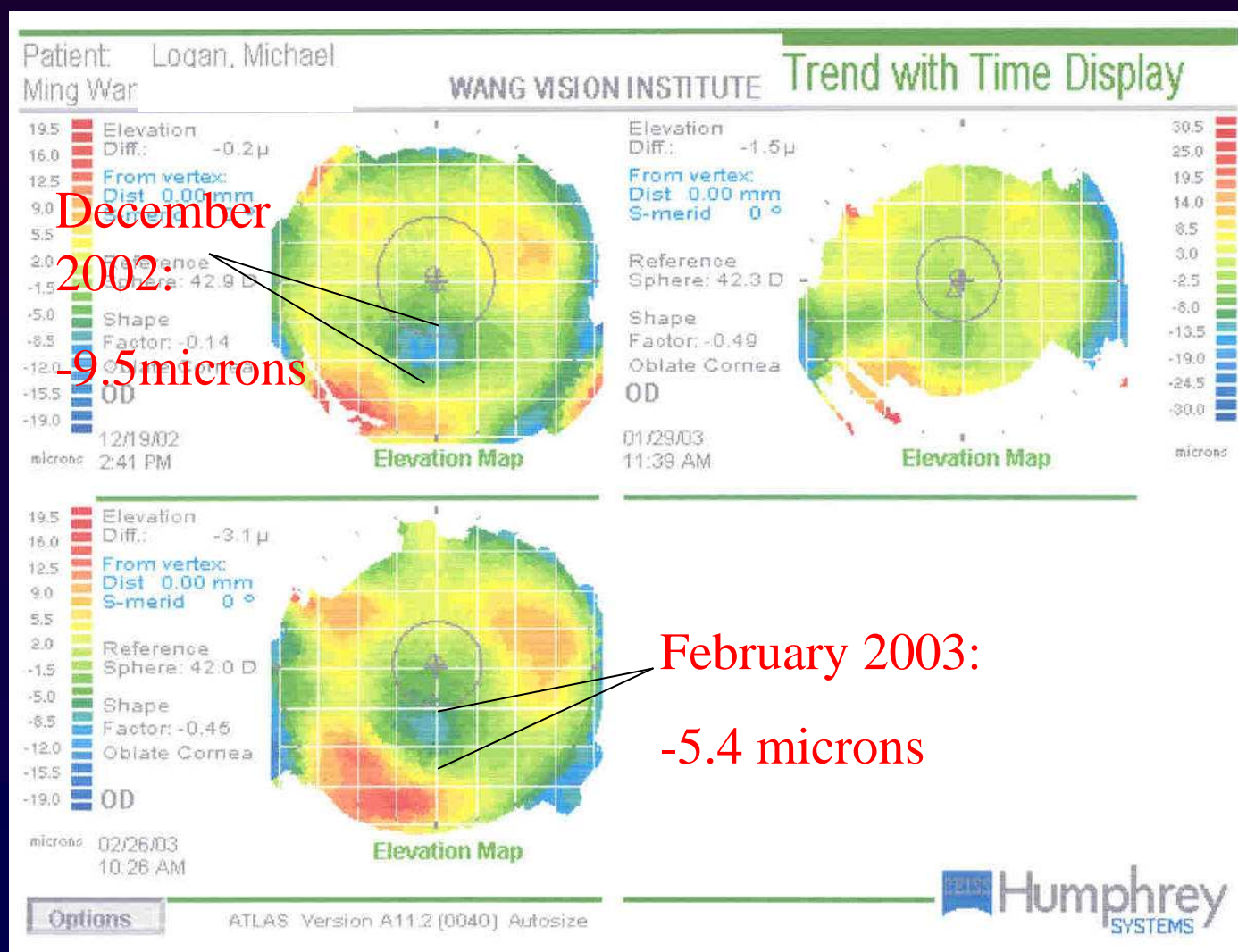


# Case ML: Self resolution of decentration

- 4 months PO
  - CC: “vision is clearing, plug helped”
  - VA <sub>sc</sub> 20/40+2
  - MR  $-1.50+0.75 \times 100$  20/20 No distortion!  
“Significant improvement in shadows with refraction”.



# Case ML: Time course of self-resolution of decentration





# Case ML: Self resolution of decentration with dry eye treatment

- 20/20 BVA with spectacle correction with full resolution of ghosting by treating the ocular surface disease (dryness)
- No need for Custom-CAP!



# CustomVue Ablation: Wavefront-guided

Using wavefront to correct decentered ablations,  
when

1. The decentration is not too severe;
2. WaveScan can map;
3. WS indeed show high coma;
4. WS refraction is similar to MR



## Case RC (Custom treatment of decentration)

42 yo Female “tired of wearing glasses”

MR: OD -7.75+1.00 x 010, 20/20

OS -10.20+1.00 x 175, 20/20

Pach's: OD 552 (ave), OS 560 (ave)

Good ocular health and TPG

Plan: LASIK for distance OU using  
Intralase (90% OD, 80% OS)



RC: 1 day s/p ML

VA's OD 20/30, OS 20/100

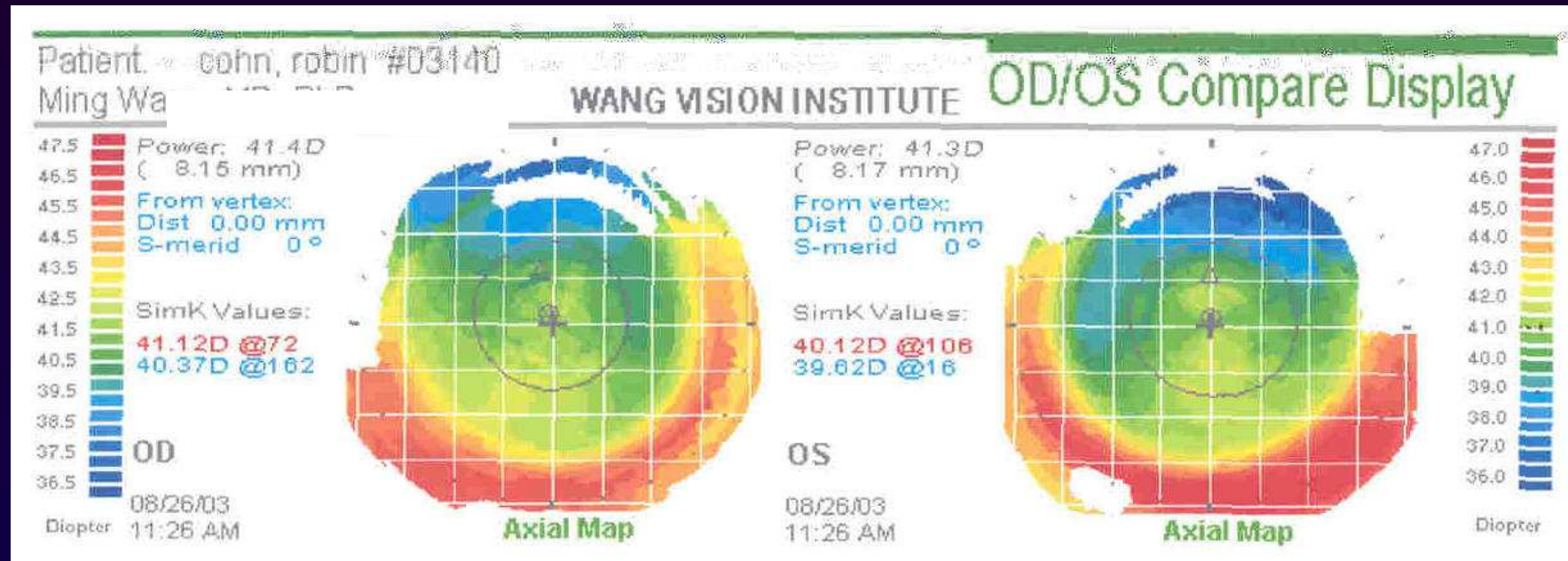
Flaps in place, no inflammation, striae  
or debris

Moderate edema OS.

Tx'd with Pred (4/3/2/1 x 1 wk)



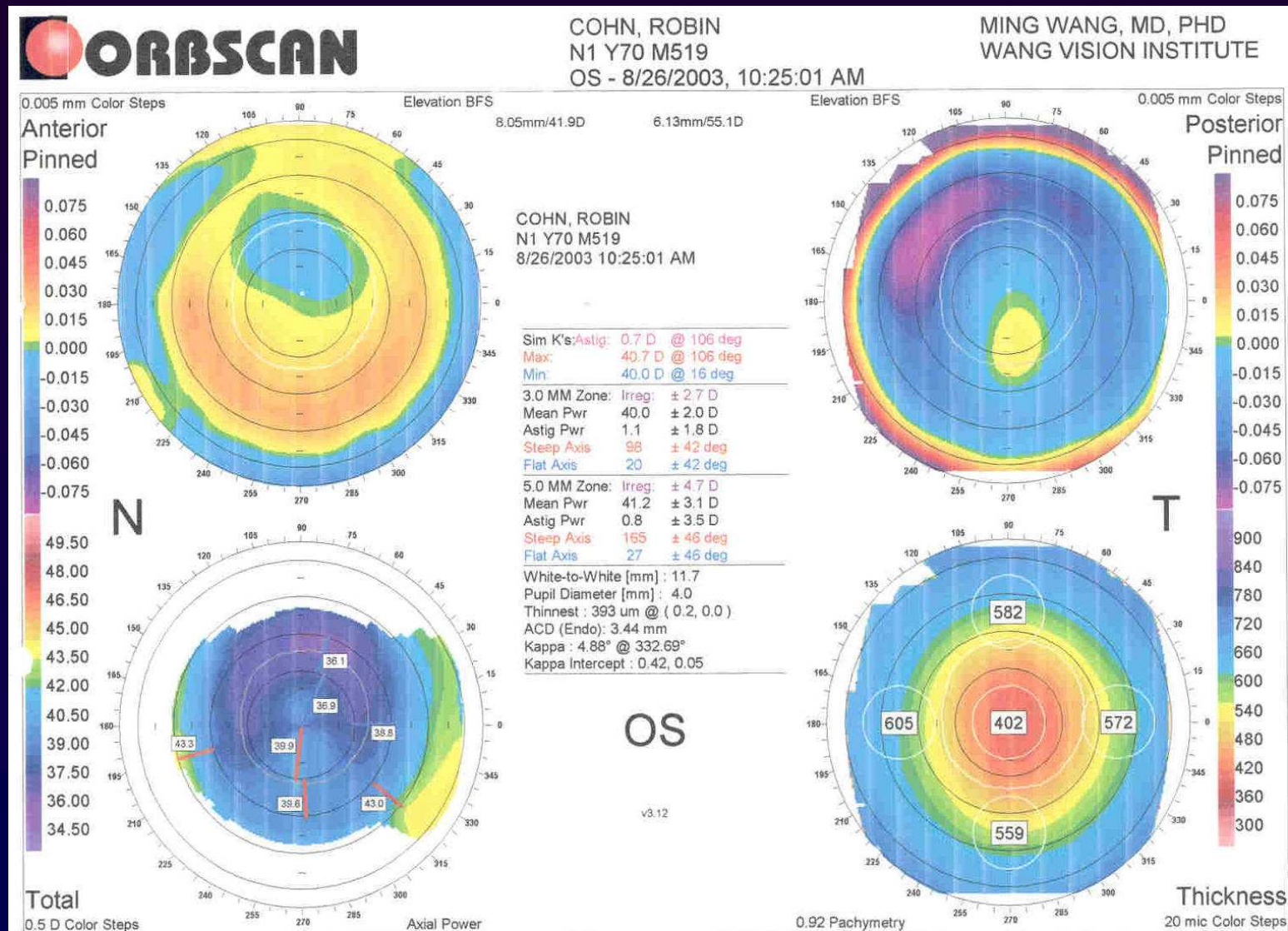
# RC decentration os s/p ML



3 mos PO: slightly decentered ablations on Atlas OS  
VA OD 20/30, MR -0.50D 20/30+1  
VA OS 20/100, MR -2.00 20/30 (blurry)

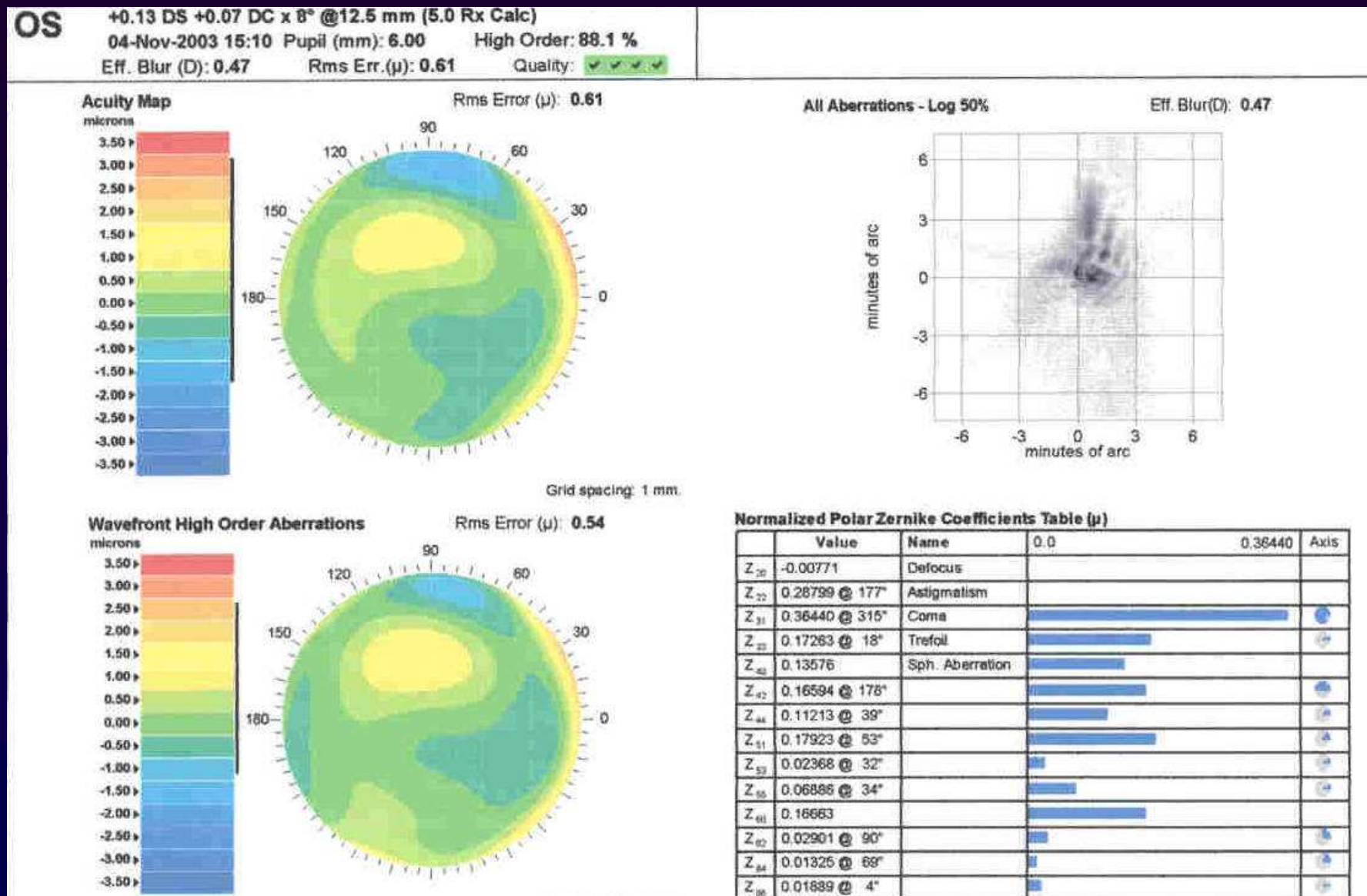


# RC 3 mos s/p decentered ML: Orbscan OS



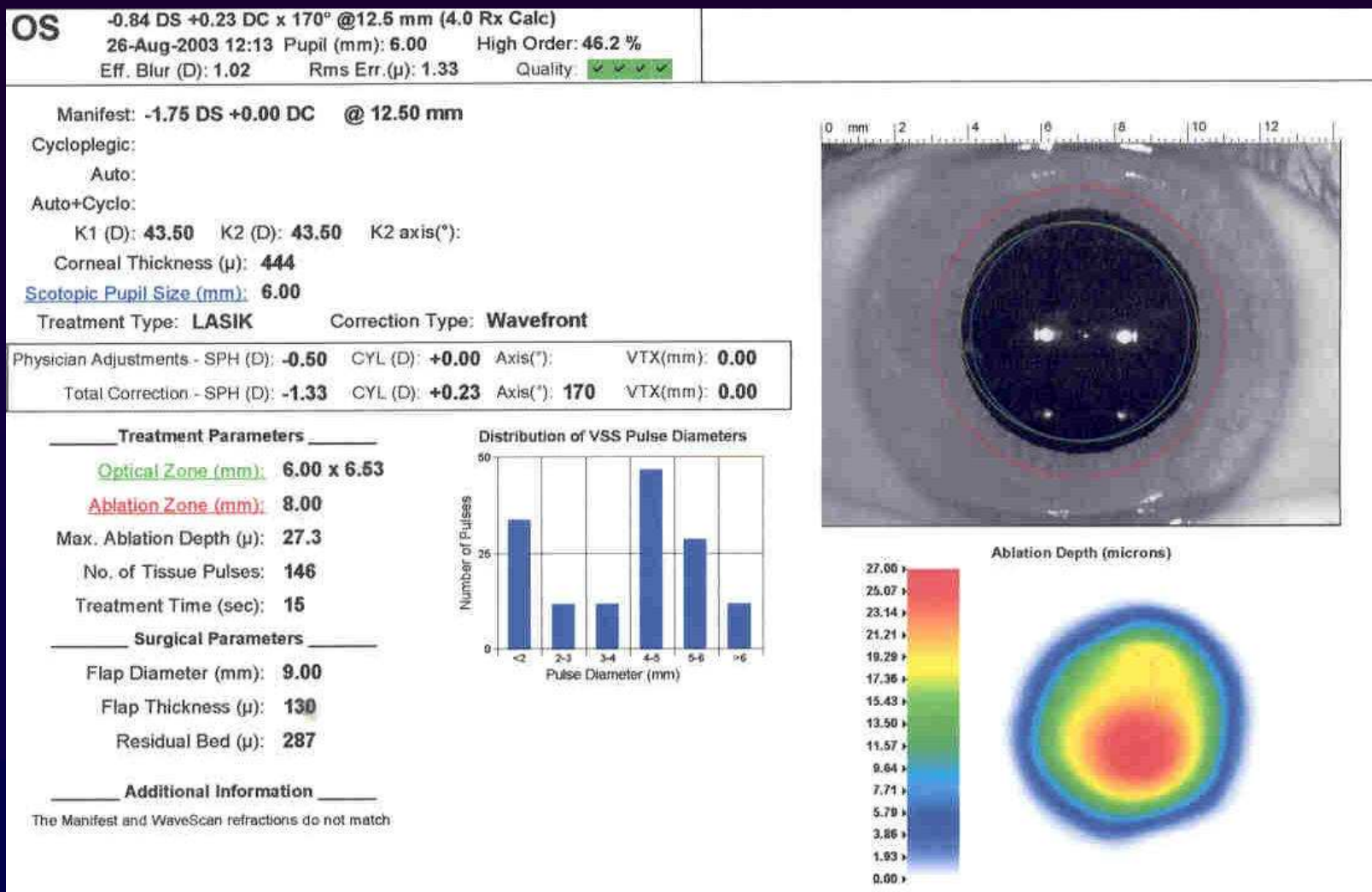


# RC s/p decentered ML os (high coma)



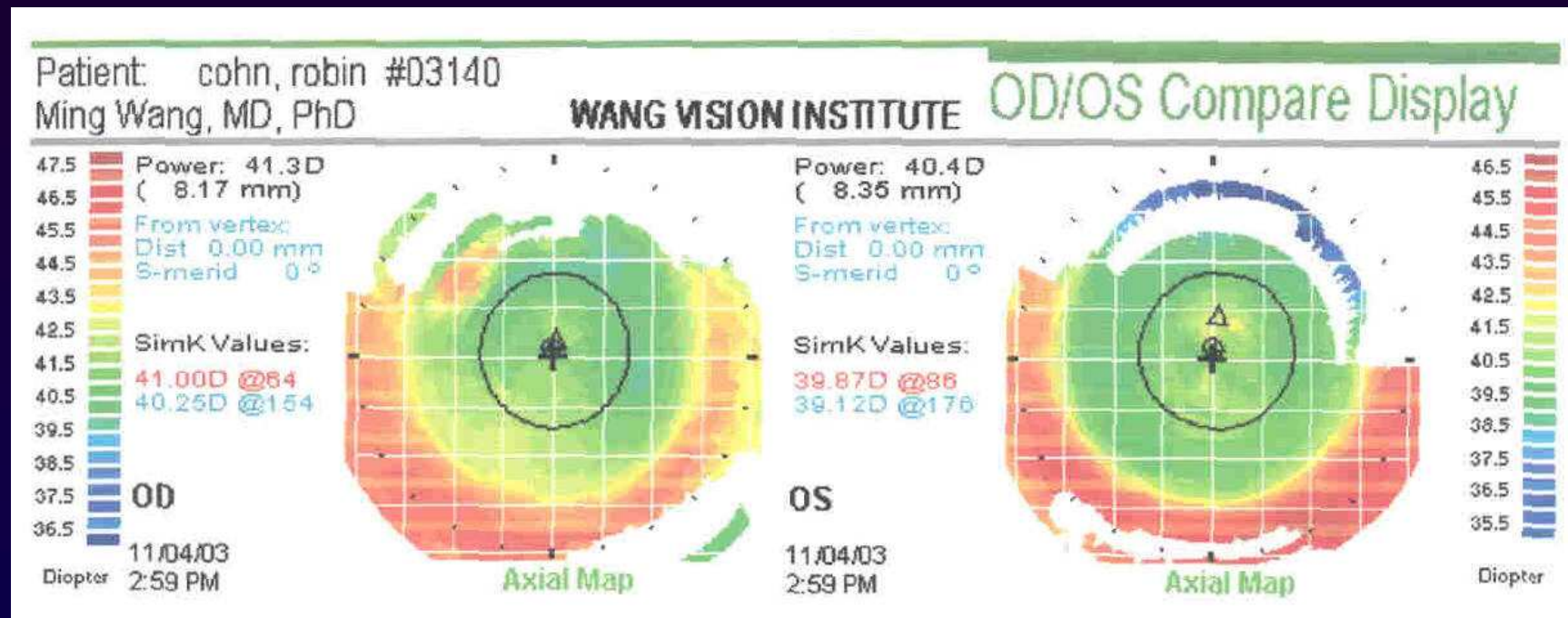


# RC: CustomVue treatment for decentered ML os





# RC S/P CustomVue treatment for decentered ML os



6 weeks: OS 20/25 “Doing well”

AR -0.50+0.25 x 100.



46.5  
45.5  
44.5  
43.5  
42.5  
41.5  
40.5  
39.5  
38.5  
37.5  
36.5  
35.5  
Diopter



# Custom treatment for decentered ML OS (DG)

45 yo Female complaining of:

Monocular diplopia, OS

“Difficulty with night glare” OU, OS > OD

“Glasses for night driving don’t help”

Original RX before ML was:

OD -7.50+1.25 x 005, 20/25

OS -9.75+2.00 x 20, 20/20

S/P Lasik May 2000

Enh OS December 2000.

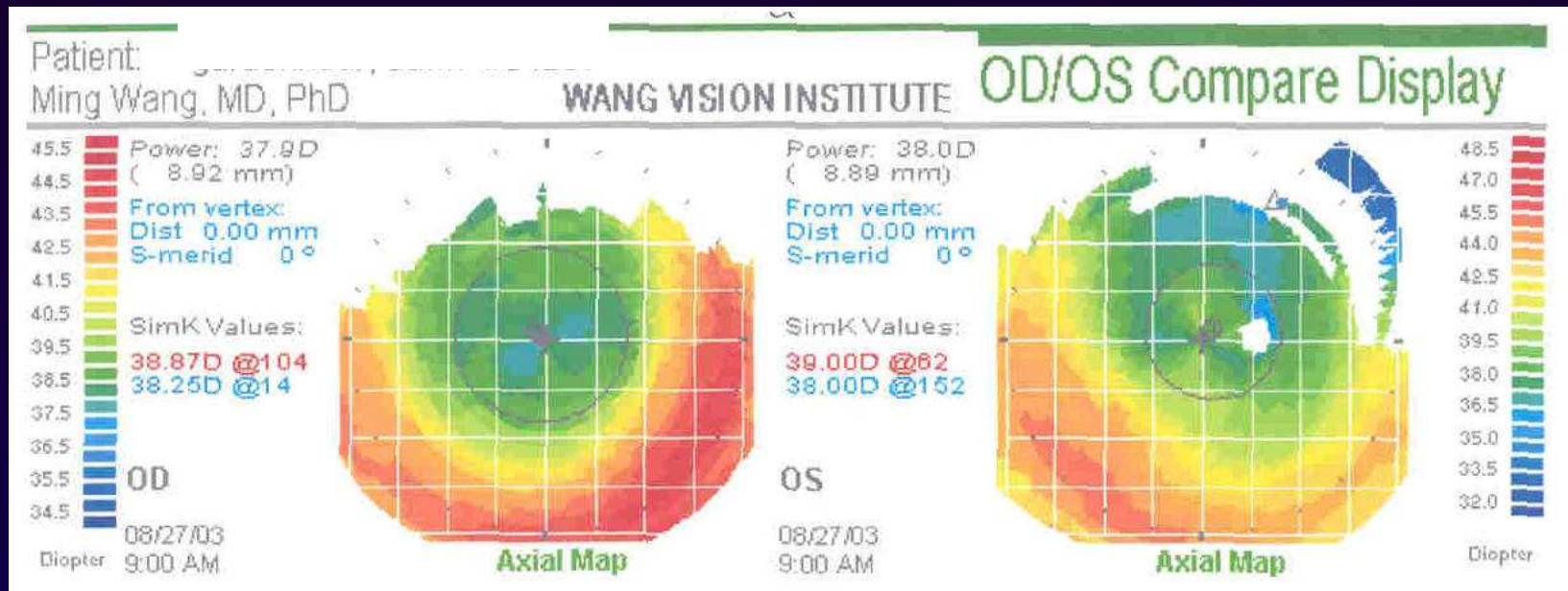

# DG with decentered ML OS

- MR OD -0.50 DS, 20/25
- MR OS -0.75+0.25 x 55, 20/30  
(blurry) with only 10% improvement  
in vision subjectively with MR
- Cyclo OS -1.50 DS, 20/40 (blurry)
- Wavescan RX -1.45+0.44 x 64, WS  
CAN map AND agrees with MR.



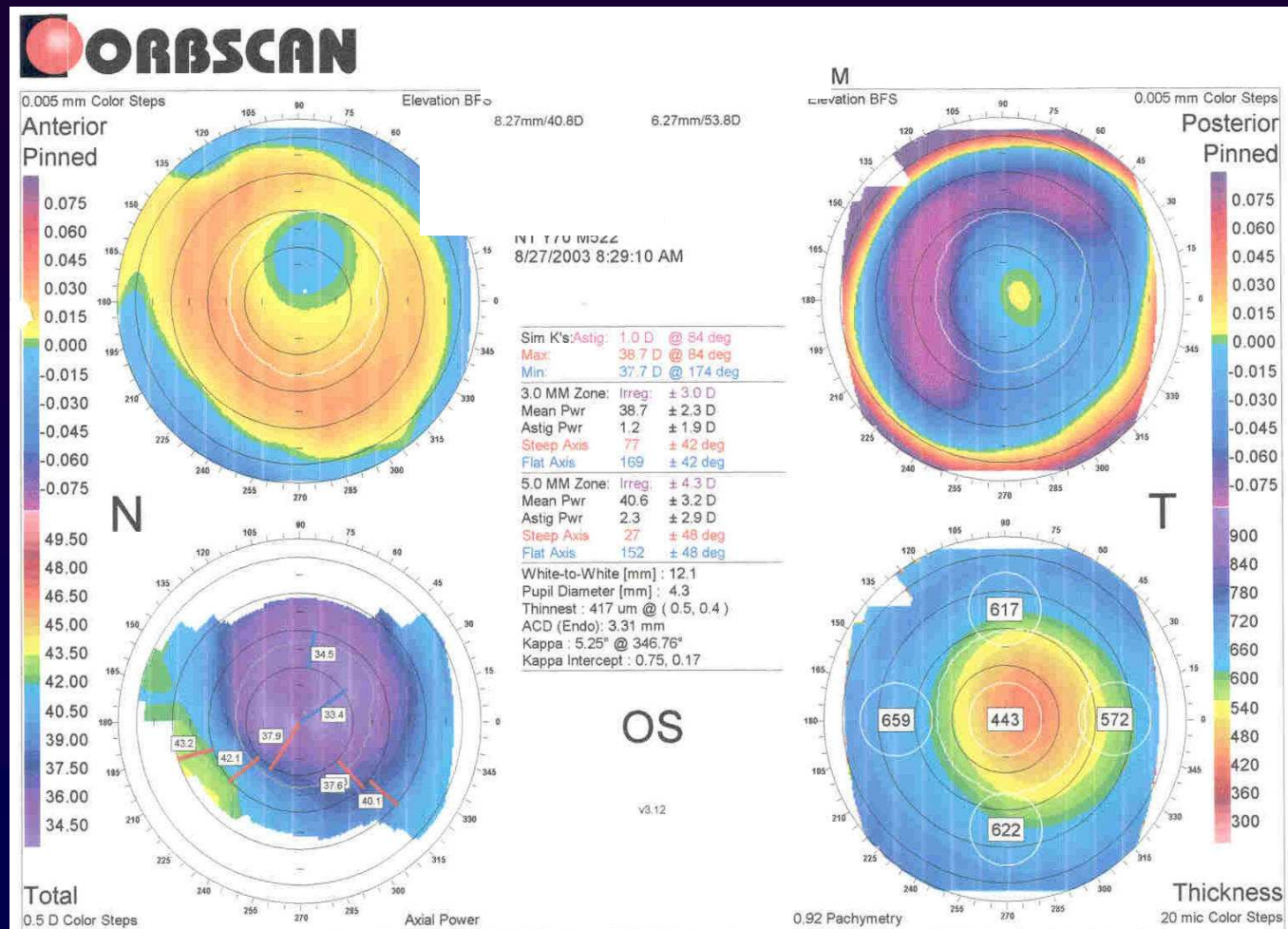
# DG with decentered ML os



US pach's OD 479 (ave), OS 469 (ave)



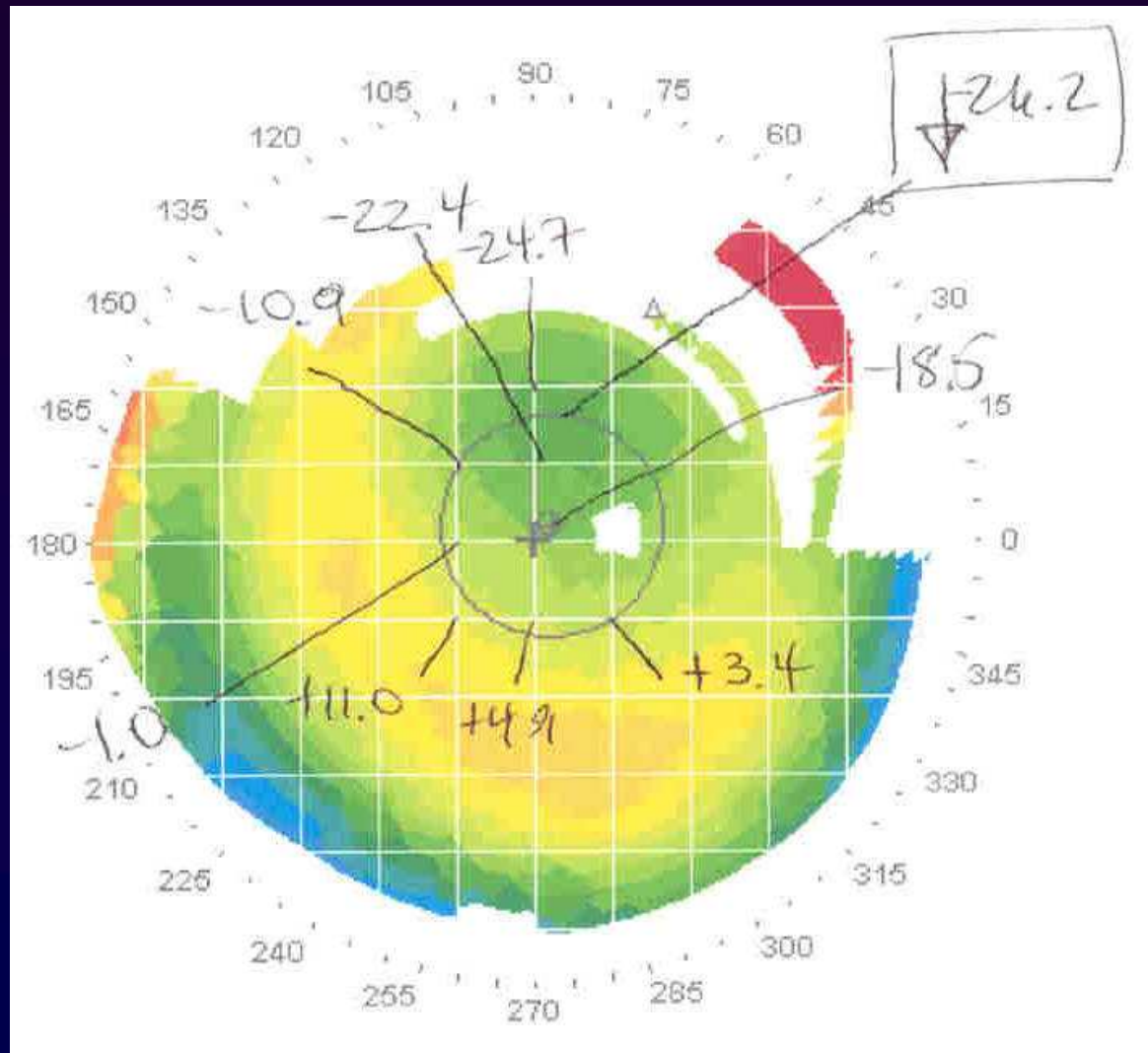
# DG superioly decentered ML OS (elevation)





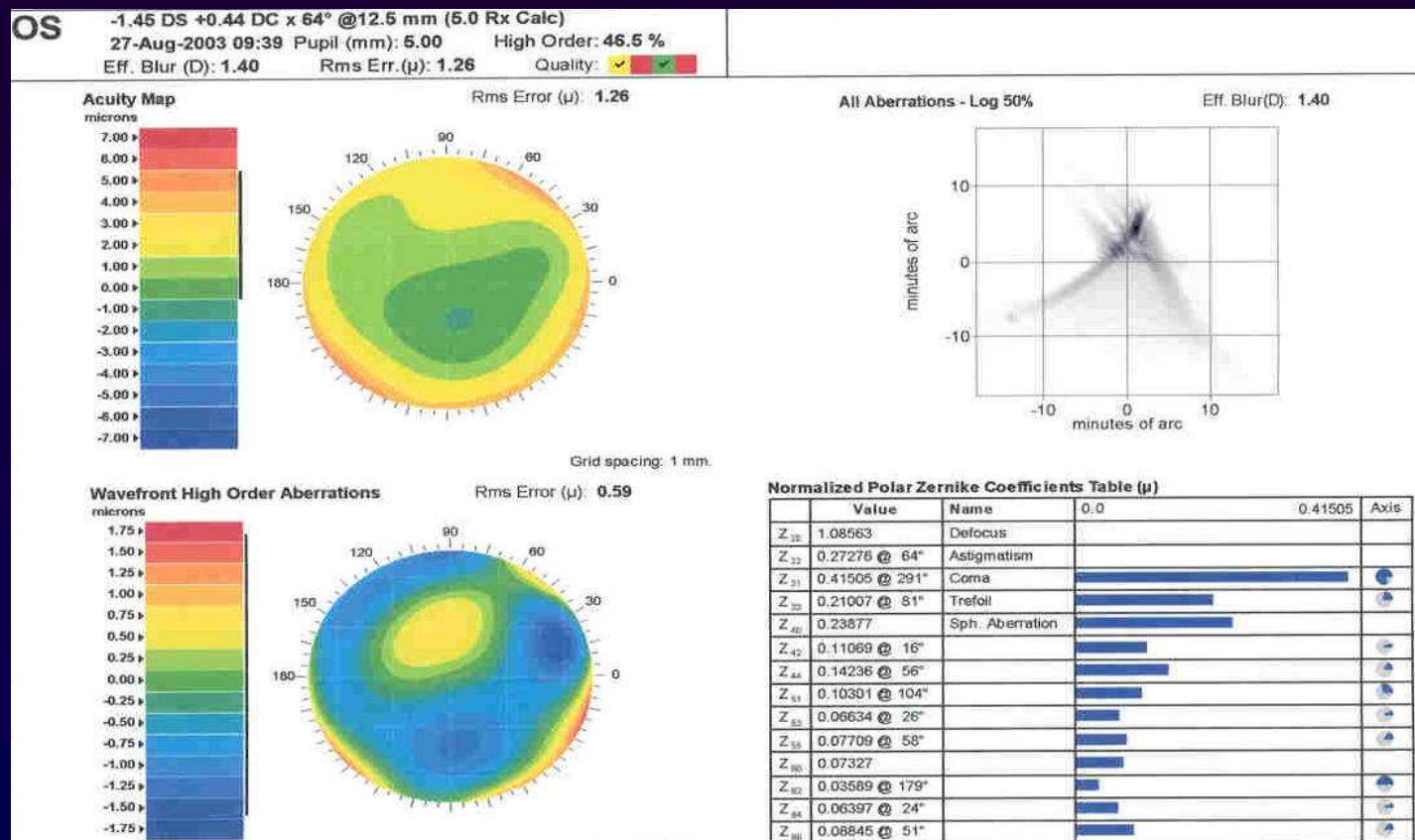
# DG height values OS on elevation

Values on elevation map show significant decentration



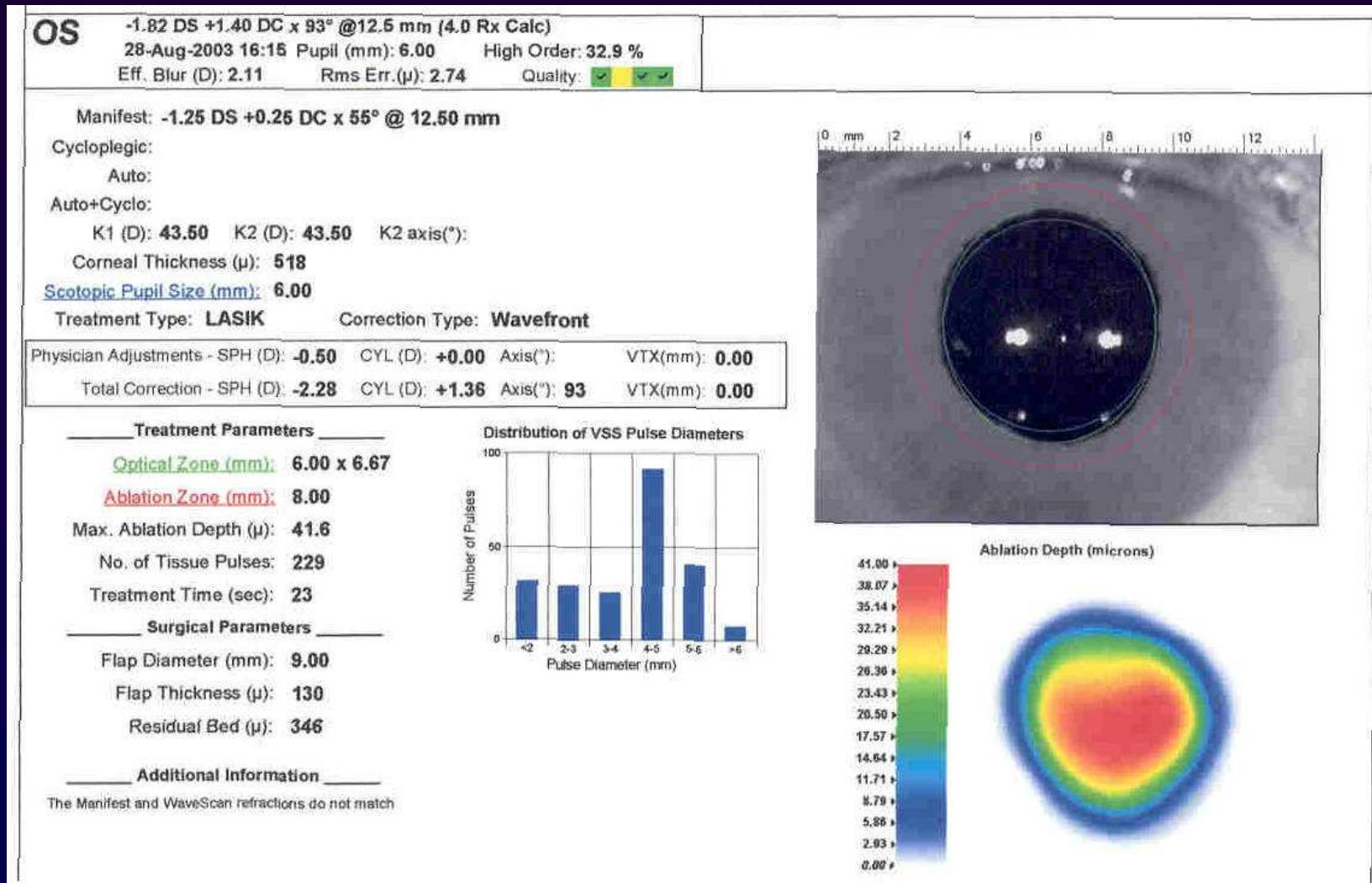


# DG Wavescan map for the decentered ML OS (high coma)



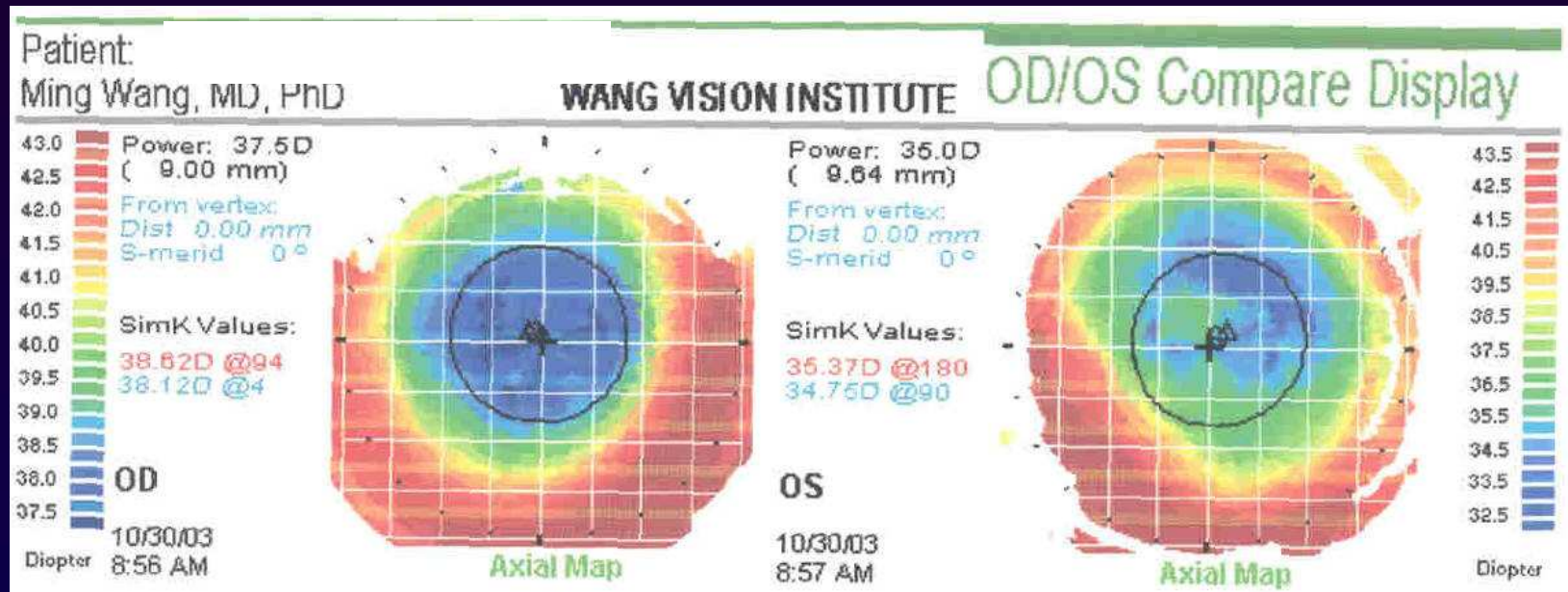


# DG CustomVue treatment plan for decentered ML os





# DG s/p CustomVue treatment for decentered ML os



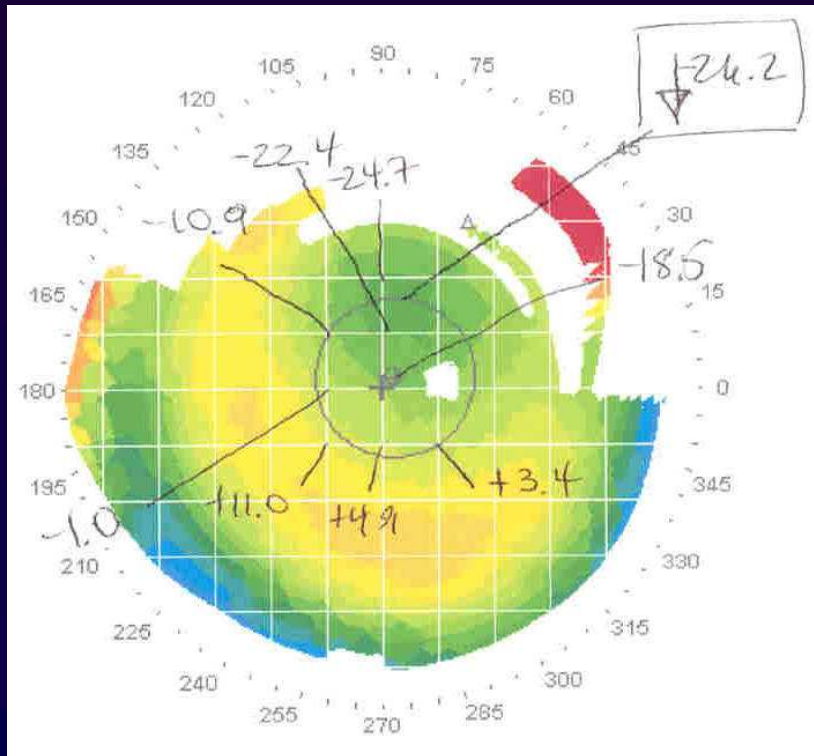
At 3 months:

VAsc 20/30

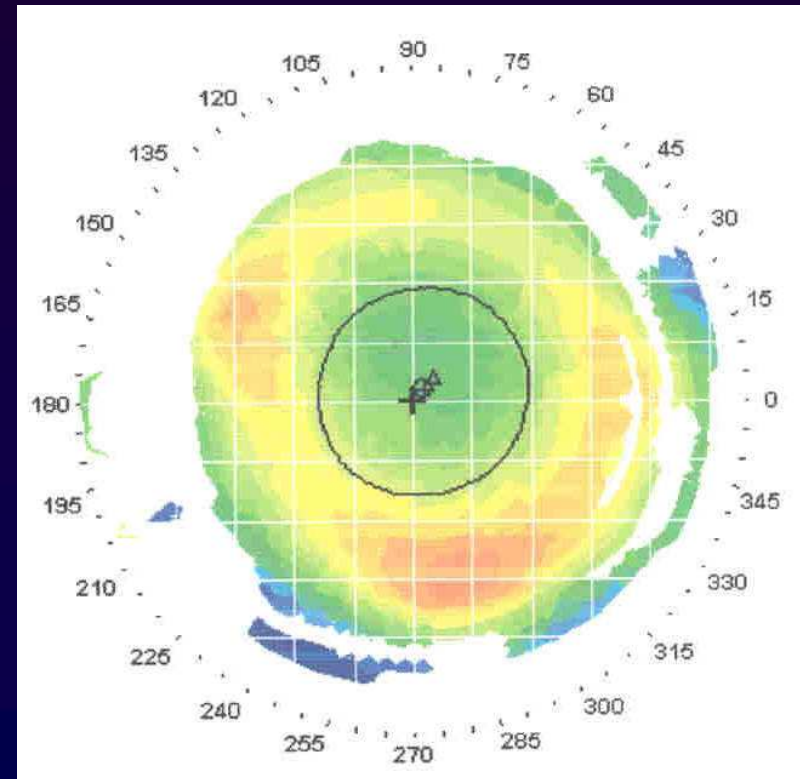
MR +1.75 20/25+ with **no diplopia**



# DG with decentered ML OS, pre-custom treatment and post-custom



**Pre-custom**



**After-custom**



# Strength and weakness of C-CAP for treating decentered ablation (sg)

## 1. Strength:

Large scale treatment, can “pull” the ablation back to center, in severely decenter-treated corneas in which WaveScan can’t map;

## 2. Weakness:

Trial and error geometric shapes;

Has to have another refractive treatment;

## 3. Cautions:

Always look at the elevation map;

Keeping in mind that some decentration will self resolve (with DES treatment for example).



# Custom Guided Treatment for decentered ablation (pg)

1. Strength:

Addresses the refractive error; more predictable (customized to the extent of decentration);

2. Weakness:

For severely decentered treatment, wavefront often can't map, or coma not dominant, or its refraction does not agree with MR;

3. Cautions:

Custom treatment secondarily address the topographical issues – less control;

Wavescan refraction is often LESS accurate in post-keratorefractive surgery eyes.



# Summary: a logical and sequential approach to treating irregular astigmatism (decentration) using C-CAP and CustomVue – VISX

- Be sure the decentered ablation is the **reason** the VA is reduced. RGP VA is important!
- C-CAP treatment work well in some **severely** decentered cases
- C-CAP induces refractive error changes, usually NOT in a positive way, and hence will need secondary refractive treatment;
- Wavefront CustomVue can treat, though imaging in severely decentered cases is hard. It is affected by lens HOA;
- Ideal treatment: topography-guided treatment

**New book: “Irregular Astigmatism” (Wang eds, SLACK)**

